

Idiopathic Pericarditis

Dan L. Hobbs, M.S.R.S., R.T.(R)(CT)(MR), is an associate professor in the department of radiographic science at Idaho State University in Pocatello.

In early March 2005, I woke up with severe pain in my chest. I was having all of the clinical symptoms of a heart attack, including substernal chest pain that radiated to my left shoulder and arm. I thought to myself, "This can't be happening. I've read about this and have studied the signs and symptoms, but I'm not prepared for this to happen to me!" I woke my wife up, told her what was going on and headed to the emergency room (ER).

On arrival, I was ushered immediately into the cardiac suite. An electrocardiogram (ECG) tech came in the room and started placing patches all over my body. As she was finishing, I heard the sound of a portable unit coming down the hall. The sound of the motor was familiar, and I knew what was about to happen. A former student of mine entered the room. He looked nervous as he placed the cold cassette behind my back. Then he stepped back and anxiously said, "Take in a deep breath." The exposure was made, and he left the room to process the radiograph. I later learned that he clipped my costophrenic angle and pleaded with the radiologist, "Please don't make me do it again; the patient is Dan Hobbs." Later, I laughed as that story was told to me. However, for now I was an active participant in an all-too-common scenario. This time it seemed a lot different – I was the patient.

The ER physician came into the room and said, "The ECG results are normal, except for an elevated ST segment." I asked, "What does that mean?" He started to explain, but before he could get the words out of his mouth, the ER nurse interrupted and placed the sublingual nitroglycerin under my tongue. "Whoa!" I said, "That's a weird sensation." Immediately, I felt my blood vessels dilate to the point of rupture. The feeling was similar to the adrenaline rush I experienced working multicaseualty traumas as a night tech. However, the difference was an immediate migraine headache. It hurt worse than the chest pain! I was surprised

as the nitroglycerin opened up pathways leading to brain cells that I didn't know existed. I groaned and turned on my side to get away from the glaring lights.

My family physician arrived within the hour and, after consultation with the ER physician, admitted me to the hospital. I'll skip the details of the 2-day experience as an inpatient. To summarize, the stay included a barrage of tests. First, it was the thallium stress test, more commonly called the treadmill exam. I dreaded running as my nuclear medicine friends observed my gait. Next, the echocardiogram was performed; it was easy compared to running on the treadmill. Finally, the diagnosis was made using the computed tomography (CT) exam. It was in the CT suite that I learned I was experiencing pericarditis. If that wasn't enough, it was the contrast injection that I remember most. I have performed this exam thousands of times on others, but not until that moment did I truly understand how my patients really felt. I remember saying to the CT tech, "I think I urinated on the table, I'm so sorry." Thankfully, like numerous other patients who have experienced this, it was just a sensation.

This experience will be one that I will not soon forget. It made me stop and think about the important things in my life and just how short life really is. My love for my wife and family is rejuvenated. Sometimes we forget about what is really important, and this experience has forced me to step back, take a look at life and count my blessings.

Consequently, I will take this opportunity to discuss pericarditis. To do this I will first describe the disease, the anatomy of the pericardium and the method used to obtain the CT images. The article will conclude with CT images obtained in several orthogonal planes, which demonstrate the pericarditis.

Description

Pericarditis is an inflammation of the sac, or pericardium, that surrounds the

heart. Fluid accumulation within the pericardium can be life-threatening. When blood or fluid builds up within the pericardium, it causes pressure, which can result in cardiac tamponade. As a result, the ventricles do not expand fully, thus they do not fill with blood adequately. This diminishes the blood supply in the pulmonary and systemic circulation and often causes death.

Grimm and Hesse¹ list several known causes for pericarditis. They include viral, bacterial, fungal and human immunodeficiency virus origins. Other known causes include myocardial infarction, radiation treatments, chest trauma, malignancy and causes related postoperatively to open-heart surgery. Likewise, collagen vascular disease, such as rheumatoid arthritis, can cause pericarditis.¹

I was diagnosed with idiopathic pericarditis. It is the most common form of acute pericarditis. The term idiopathic describes an obscure or unknown cause. It accounts for approximately 1 in 1000 hospital admissions, and no specific cause can be found in most cases.² Idiopathic pericarditis generally is not life-threatening and is treated with high doses of nonsteroidal anti-inflammatory medications. Examples include Ibuprofen, Aspirin, Naproxen and Nabumetone.

Anatomy

The pericardium is a 2-layer membrane that surrounds the 4 cardiac chambers of the heart. (See Fig. 1.) It includes an outer fibrous layer and an inner serous layer. The outer fibrous layer, or fibrous pericardium, surrounds the more delicate double-layered sac. This thin serous-layered sac has an inner layer called the visceral pericardium, which covers the surface of the

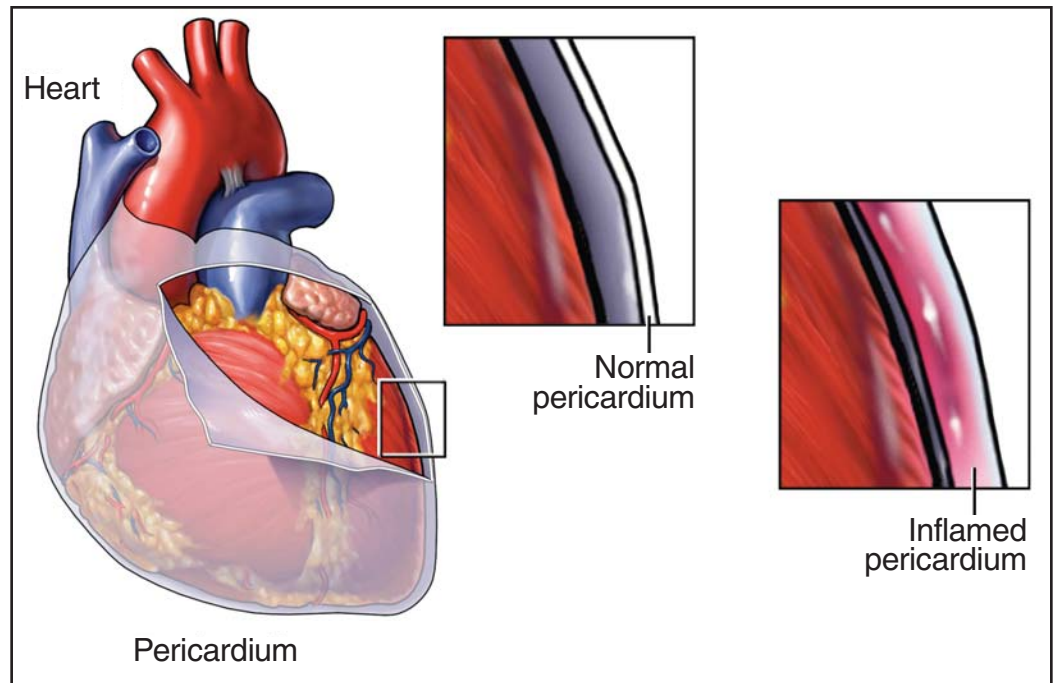


Fig. 1. Anatomy of the pericardium. This diagram shows the anatomical relationship of the pericardium and the heart. The pericardium is composed of an outer visceral layer and an inner parietal layer. An inflammatory condition of the pericardial space is called pericarditis. (Reprinted with permission from Nucleus Medical Art. www.nucleusinc.com. All rights reserved.)

heart. The serous outer layer is called the parietal layer. Dwyer and Khalil mention that “the parietal serous pericardium is attached to the fibrous pericardium.”³ It is also interesting to note that this outer parietal layer has attachments to the diaphragm, sternum and costal cartilage, thus acting as a protective sac for the heart.

The space between the 2 layers is called the pericardial cavity. It contains serous fluid, typically between 15 mLs and 50 mLs.⁴ This fluid helps reduce friction between the pericardial membranes as the heart beats. One of the pericardium’s primary functions is to act as a protective barrier for the heart by limiting the spread of infection via adjacent structures.⁵ Therefore, pericarditis is an inflammation of the lining of the heart.

Making the Diagnosis

The provisional diagnosis of my case was myocardial infarction. The differential diagnoses included pulmonary embolism, unstable angina, acute aortic dissection and pericarditis. Myocardial infarction was ruled out by a nuclear thallium stress test. Additionally, echocardiography was performed to assess the heart’s

function and structures. Echocardiography has a higher efficacy than CT for evaluating small volume effusions⁶; however, in my case the ultrasound proved uneventful. CT and magnetic resonance imaging were still viable options. Luckily, the CT exam came first and it provided the answer.

Methods

A high-speed, high-resolution multidetector thoracic CT scan was performed using a Toshiba Aquilion 64-slice CT scanner (Toshiba America Inc, New York, NY). Axial sections were acquired with a volumetric acquisition of 0.5 mm thickness, 400 millisecond gantry revolution and 30 cm field of view. Multiplanar reformations (MPR) were obtained in several orthogonal planes with varying slice thickness. Intravenous access

was made via the left median cubital vein with the administration of 75 mL of Omnipaque 350 (Amersham Health) at a rate of 4 mL per second, from 20 mm inferior to the xiphoid process to 30 mm superior to the jugular notch. This proved successful in demonstrating the entire lung parenchyma and mediastinal components.

Scan parameters included a kilovoltage of 120 kV and tube currents ranging from 370 mA to 500 mA using ^{SURE}Exposure (Toshiba America Inc, New York, NY). This method helps reduce dose by as much as 40% compared to using a nonvariable tube current. It works by providing "optimum image quality at minimum patient dose by adjusting the tube current during scan-

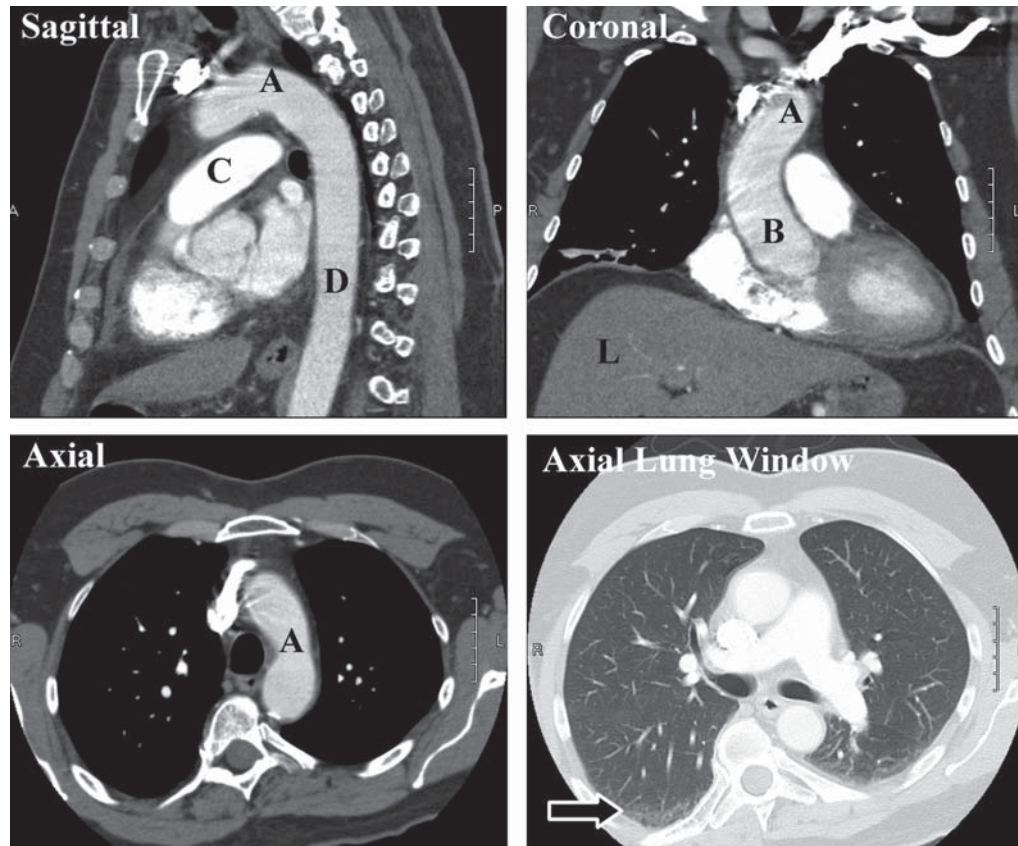


Fig. 2. This set of orthogonal images was used to rule out an aortic dissection and pulmonary embolus. The 3 images labeled "sagittal," "coronal" and "axial" are a subset of many images that were used in the evaluation to rule out dissection. The letter "A" represents the arch of the aorta, "B" represents the ascending aorta and "D" represents the descending aorta. Additional anatomy shown includes "C," which is the main stem of the pulmonary artery, and "L," which denotes the liver. The image labeled "Axial Lung Window" demonstrates the pulmonary vasculature in a parenchymal window and is 1 of many images used to rule out pulmonary embolus. The arrow in this image denotes an incidental finding of atelectasis, which can also be seen in the contralateral lung base.

ning."⁷ Images were evaluated in mediastinal settings (window = 500, level = 50) and parenchymal settings (window = 1600, level = -550). Coronal and sagittal images were also reconstructed in 2 mm slice increments and evaluated in both mediastinal and parenchymal window settings.

Results

In the case presented, there was no evidence of aortic dissection or pulmonary embolism. (See Fig. 2.) An axial image through the heart demonstrates the pericarditis. (See Fig. 3.) Likewise, in this study the coronal and sagittal planes were also evaluated. These images

demonstrate the pericarditis equally as well as the axial images. (See Figs. 4 and 5.) It is interesting to note that the printed images in this article are not nearly as impressive as the real-time images that are viewed electronically by the CT technologist. Paging through these images on a computer monitor is incredible! It brings a new dimension to viewing anatomy.

In years past it has not been possible to view CT examinations in submillimeter sections through MPR and 3-D imaging to the extent made possible today. For example, because of machine limitations, it has been nearly impossible to image the entire thorax, abdomen and pelvis in submillimeter sections all at one time, let alone in one breath hold. Presently, spiral CT scanning has made this a reality. The added benefit is that 64-slice technologies allow for image quality to be the same in all directions. This means that images acquired on a 64-slice CT scanner can be reformatted in different submillimeter orthogonal sections, which are as good as the original axial images. The term that defines this is isotropic imaging. Rydberg et al and associates explain it this way, "Coronal and sagittal reformats, in addition to axial images, create a new standard of viewing normal anatomy as well as pathology."⁸ This is thrilling! It is opening the gateway to the next era of imaging. Some think that eventually most images will be viewed by using 3-D data sets and that there will be a move away from slice-based imaging.⁹ Regardless, the images presented in this case do provide several examples of isotropic imaging obtained by 64-slice technology.

One thing that is not discussed in this article is the increase in patient dose that is acquired by reducing slice thickness and increasing volume scanned. ^{SURE}Exposure is one way that some manufacturers of CT equipment are addressing this concern. This needs to be addressed because 256-slice CT scanners are on the horizon.

Discussion

The anatomy involving epicardial and mediastinal structures has not been adequately imaged by previous generations of CT scanners. However, progression of spiral CT technology has improved the ability to decrease cardiac motion. It also has allowed for reductions in image slice thickness to adequately evaluate pathology that has been hard to evaluate in the past.

In conclusion, this article has described the anatomy of the pericardium and several thoracic CT images have been presented. A protocol used for performing a high-speed, high-resolution multi-detector thoracic CT scan has been reviewed. Additionally, several isotropic

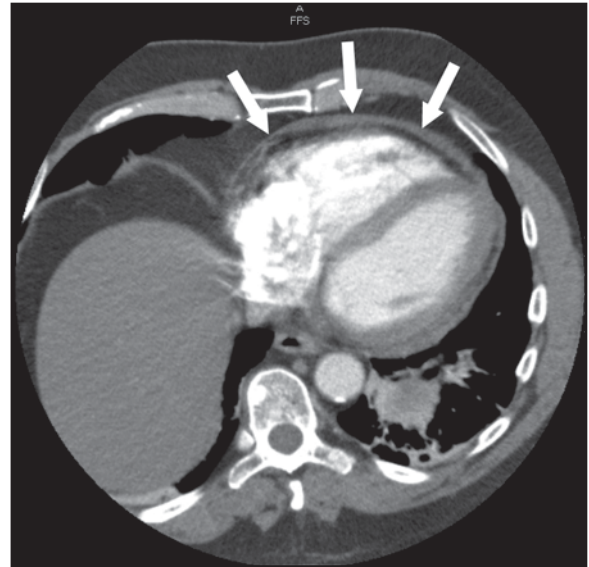


Fig. 3. Axial image through the level of the heart. Arrows denote pericarditis in the anterior pericardium.

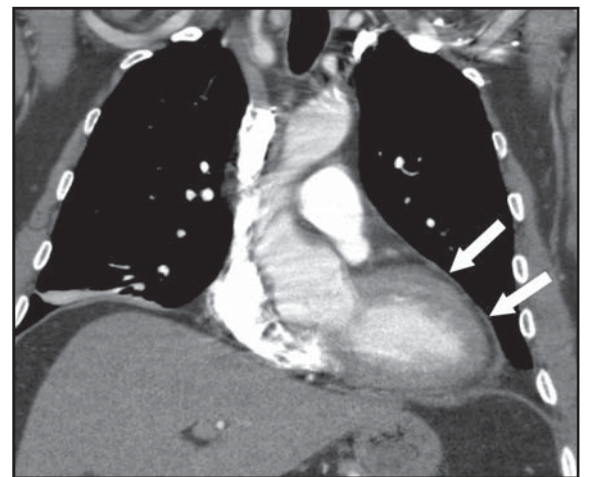


Fig. 4. Coronal image through the level of the anterior heart. Arrows denote pericarditis.

images demonstrating pericarditis were presented.

This has been a personal experience for me. The positive side of my diagnosis is that my experience as a CT technologist has helped me through this ordeal. On the other hand, I now have greater empathy for others experiencing similar episodes in their lives. Hopefully, you have gotten to know me on another level through reading this article. At any rate, the next time you have the opportunity to perform a CT exam to rule out pulmonary embolism remember, it may not be an embolus that you find. ♦

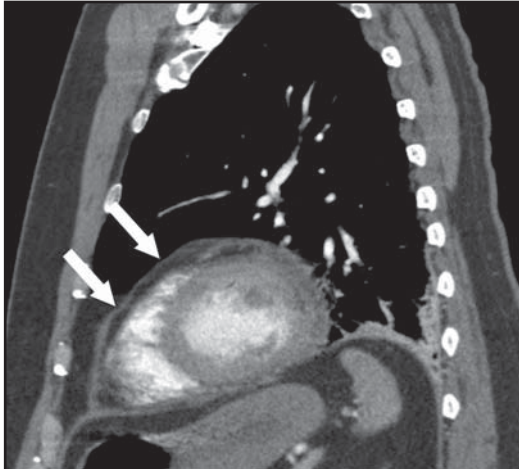


Fig. 5. Sagittal image through the level of the anterior heart. Arrows denote pericarditis.

References

- Grimm RA, Hesse B. Pericardial Disease. The Cleveland Clinic Disease Management Project Web site. Available at: www.clevelandclinicmeded.com/diseasemanagement/cardiology/pericardial/pericardial.htm. Accessed September 21, 2006.
- Pericarditis. MedicineNet.com Web site. Available at: www.medicinenet.com/pericarditis/article.htm. Accessed September 21, 2006.
- Dwyer RT, Khalil T. Computed tomographic diagnosis of unsuspected pericarditis. *JHK Coll Radiolo.* 2003;6:36-39.
- Oyama N, Oyama N, Komuro K, Nambu T, Manning WJ, Miyasaka K. Computed tomography and magnetic resonance imaging of the pericardium: anatomy and pathology. *Magn Reson Med Sciences.* 2004;3(3):145-152.
- The Pericardium. Emergency-Medicine.info Web site. Available at: www.emergency-medicine.info/articles/pericardium.html. Accessed September 21, 2006.
- Olson MC, Posniak HV, McDonald V, Wisniewski R, Moncada R. Computed tomography and magnetic resonance imaging of the pericardium. *Radiographics.* 1989;9:633-649.
- Toshiba Medical Systems Web site. Available at: www.medical.toshiba.com/clinical/radiology/aquilion64-683-683-476.htm. Accessed September 25, 2006.
- Rydberg J, Kumaresan S, Lall C, Hameed T, Hawes D, Kopecky K. Routine isotropic scanning of the abdomen and pelvis using a 40-channel CT scanner: value of reformatted coronal and sagittal images in showing pathology. RSNA Web site. Available at: http://rsna2004.rsna.org/rsna2004/V2004/conference/event_display.cfm?em_id=4416251&id=66601&p_navID=272. Accessed September 26, 2006.
- Keat N. Helical and multi-slice principles PowerPoint presentation. Impactscan.org Web site. Available at: www.impactscan.org/slides/impactcourse/helical_and_multi-slice_principles/index.html. Accessed September 27, 2006.

RADIOLOGIC

TECHNOLOGY

Statement of Ownership, Management and Circulation as of 9-27-06

Radiologic Technology

Publication No. 0033-8397

6 issues annually; bimonthly

Price \$7 per year, included in member dues

Publisher: American Society of Radiologic Technologists, 15000 Central Ave. SE, Albuquerque, NM 87123-3917.

Owner: American Society of Radiologic Technologists, 15000 Central Ave. SE, Albuquerque, NM 87123-3917.

No other known bondholders, mortgages or other security holders.

Circulation

	Actual	Average
A. Total No. of Copies	120,377	123,028
B. Paid and/or Requested		
1. Outside-County Mail Subscriptions	117,733	121,413
2. In-County Subscriptions	0	0
3. Sales Through Dealers, Carriers and Vendors	0	0
4. Other Classes Mailed Through the USPS	549	578
C. Total Paid and/or Requested Circulation	118,282	121,991
D. Free Distribution by Mail		
1. Outside-County	69	80
2. In-County	0	0
E. Free Distribution Outside the Mail	0	0
F. Total Free Distribution	69	80
G. Total Distribution	118,351	122,071
H. Copies Not Distributed	2,026	957
I. Total	120,377	123,028
J. Percent Paid and/or Requested Circulation	99.94%	99.93%

I certify that the statements made by me above are correct and complete.

Jason Montañó, Publishing Specialist
Communications Department