

# Lateral Positioning of the Nasal Bones Using Digital Radiography

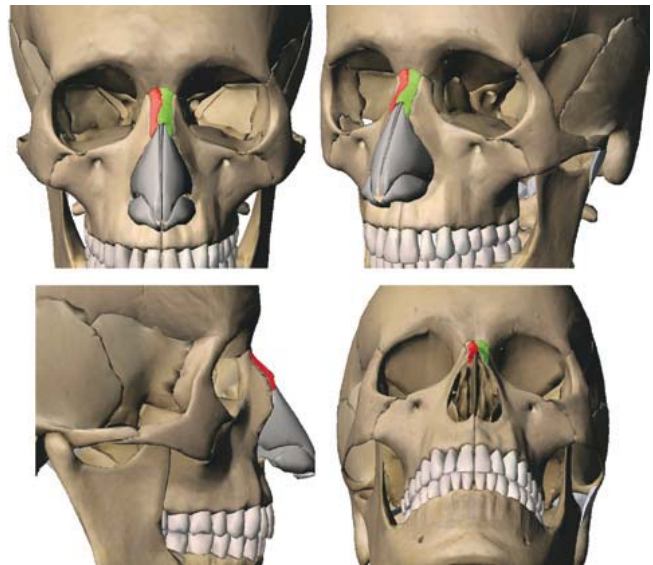
Wendy Mickelsen, MHE, R.T.(R)(M)  
 Dan Hobbs, MSRS, R.T.(R)(CT)(MR)  
 Christopher Wertz, MSRS, R.T.(R)

**T**he nasal bones consist of 2 fused bones that help to form the bridge of the nose and can vary in size among adults (see **Figure 1**).<sup>1</sup> Because the nose is a prominent facial feature, it is often the site of trauma. The nasal bones are the most commonly fractured facial bones, and these fractures are statistically more prevalent among men than women, at a ratio of 2:1, with a significant peak in the 15- to 25-year-old male population.<sup>2,3</sup> Adult nasal fractures typically result from altercations, sports injuries, motor vehicle accidents, and falls. The degree of force required to fracture the nasal bones is relatively small (25-75 lb of pressure) compared with the surrounding midfacial structures.<sup>3</sup> Patients with nasal fractures usually exhibit some degree of deformity, tenderness, hemorrhage, edema, and instability.<sup>4</sup>

In radiography, imaging the nasal bones is common. Typical protocol includes a Waters or Caldwell and bilateral lateral images. Both sides of the nasal bones are examined for comparison.<sup>5</sup> Over the years, using film-screen techniques and theory, educators taught positioning of the lateral nasal bones with the patient lying semiprone on the table with his or her head turned into either a left or right lateral position. Many newer radiography positioning books still demonstrate this practice. However, for injured, elderly, or immobile patients, this position is difficult.

## Digital Imaging Receptors

Lateral positioning of the nasal bones can be performed in a variety of ways. The advent of digital



**Figure 1.** Anatomy of the nasal bones. Reprinted with permission from Visible Body.

radiography has enabled technologists to modify their examination protocols. Consequently, lateral nasal bone positions can be achieved easily and with some ingenuity using computed and direct imaging receptors.

## Computed Radiography

For computed radiography, a technologist places an 8 × 10-inch imaging plate into the upright Bucky, setting it directly onto the bottom lip of the cassette holder. The imaging plate should be pulled out of the

## Professional Review

### Lateral Positioning of the Nasal Bones Using Digital Radiography

Bucky, maintaining a nongrid exposure technique. With a patient either standing or sitting, the technologist must adjust the height of the pulled-out Bucky until it rests directly above the patient's shoulder. The patient's cheek should be placed directly against the imaging plate.

The technologist should position the nasal bones on the center of the imaging plate and adjust the patient's head into a true lateral position, ensuring that the interpupillary line is perpendicular to the imaging plate. The technologist must then collimate to the anatomical area of interest (see **Figure 2**). Exposure factors should be similar to those of a finger exposure technique (ie, low kVp, low mAs, and small focal spot). The exposure is repeated on the contralateral nasal bone for comparison purposes.

For facilities using film-screen, this same technique can be used with a detail cassette in the upright Bucky in lieu of a computed radiography imaging plate.

#### **Direct Radiography**


For direct radiography of the lateral nasal bones performed at the upright Bucky, a technologist must remove the grid to facilitate a nongrid exposure technique (see **Figure 3**). As with computed radiography, exposure factors should be similar to those of a finger exposure technique (see **Figure 4**).

The technologist should position the patient with the nasal bones in the center of the direct radiography flat panel (see **Figure 5**). Some imaging facilities prefer not to remove the upright Bucky grid because of the replacement cost if it is dropped or damaged. In that case, a wireless detector could be used. The technologist would place the wireless detector on the rollaway holder and position the patient supine on the radiographic table with the detector directly against the downside nasal bone (ie, the one closest to the image receptor) (see **Figure 6**).

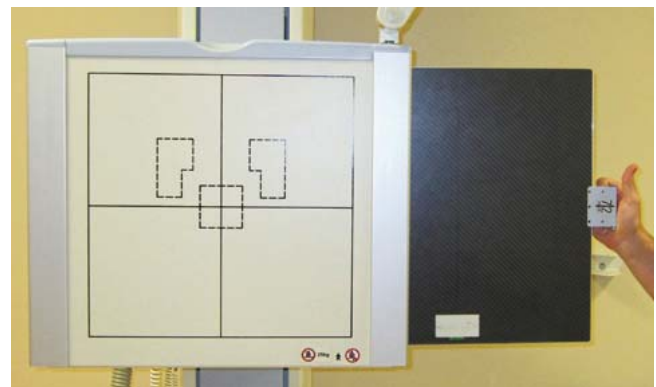
Both sides of the nasal bones are imaged. Immediately after the detector is exposed, the radiograph will appear on the technologist's workstation monitor (see **Figure 7**).

#### **Conclusion**

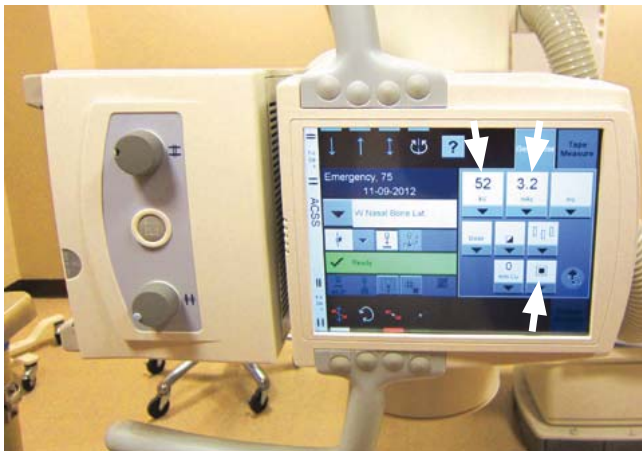With advances in technology, film-screen cassettes are becoming outdated. Wireless detectors and imaging



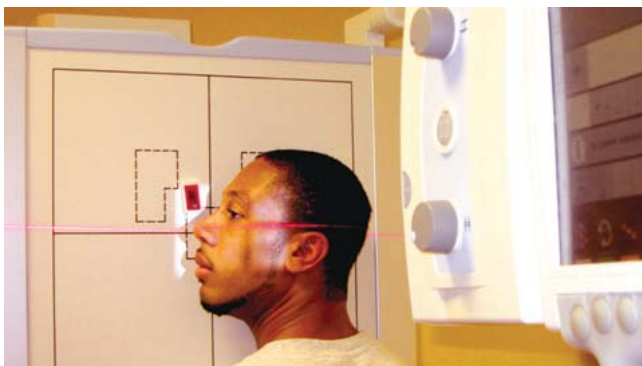
**Figure 2.** A. Computed radiography imaging plate placed on the cassette holder of the upright Bucky (arrow). B. Model is standing in a right lateral nasal bone position. Imaging plate remains in a pulled-out position to use nongrid exposure factors; image receptor is directly above the shoulder.



**Figure 3.** Grid is removed from upright flat-panel direct-radiography detector.



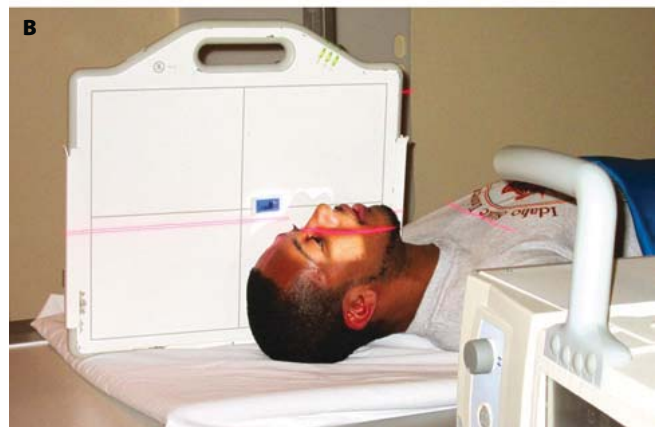**Figure 4.** X-ray tube head demonstrating digital display of nasal bone exposure factors: 52 kVp, 3.2 mAs, small focal spot.



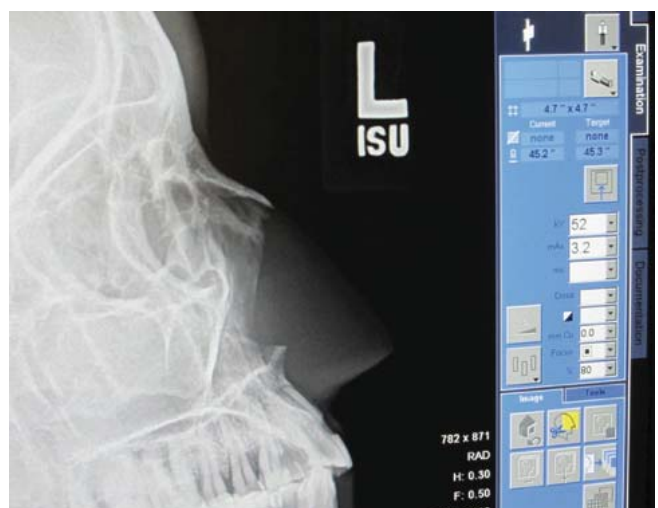**Figure 5.** Model is in a right lateral position next to direct radiography detector, with the grid removed from the upright Bucky.

plates provide opportunities for students and technologists to explore innovative ways to perform traditional studies. The result can make the examination easier and more efficient for both patient and technologist. Although obtaining images of the nasal bones is relatively straightforward, the techniques suggested in this article offer an easy approach for improving the process.

*Wendy Mickelsen, MHE, R.T.(R)(M), is a clinical assistant professor and clinical coordinator for the Radiographic Science Program at Idaho State University and a mammography and staff technologist at Eastern Idaho Regional Medical Center in Idaho Falls.*



**Figure 6.** A. Wireless detector placed on a rollaway holder. B. Wireless detector in position for an x-table digital image of the left lateral nasal bone.



**Figure 7.** Left lateral nasal bones of an x-ray phantom demonstrated on the technologist's workstation monitor.

# Professional Review

---

## Lateral Positioning of the Nasal Bones Using Digital Radiography

*Dan Hobbs, MSRS, R.T.(R)(CT)(MR), is the program director for the Radiographic Science Program at Idaho State University.*

*Christopher Wertz, MSRS, R.T.(R), is an adjunct faculty member for the Radiographic Science Program at Idaho State University and a staff technologist at Mountain View REDICARE in Idaho Falls.*

### References

1. Bontrager KW, Lampignano JP. *Radiographic Positioning and Related Anatomy*. 7th ed. St Louis, MO: Mosby Inc; 2010: 401-444.
2. Eisenberg R, Johnson N. *Comprehensive Radiographic Pathology*. 5th ed. St Louis, MO: Mosby Inc; 2012:320.
3. Mathog R, Arden R, Marks S. *Trauma of the Nose and Paranasal Sinuses*. New York, NY: Thieme Medical Publishers; 1995:23-25.
4. Smith J, Perez C. Nasal fracture imaging. eMedicine website. <http://emedicine.medscape.com/article/391863>. Accessed December 15, 2012.
5. Ballinger PW, Frank ED. *Merrill's Atlas of Radiographic Positions and Radiologic Procedures*. 12th ed. St Louis, MO: Mosby-Year Book Inc; 2012:323-336.