

Imaging Humeral Fractures

Dan L. Hobbs, M.S.R.S., R.T.(R)(CT)(MR), is an associate professor in the department of radiographic science at Idaho State University in Pocatello.

Radiologic technologists commonly are called to emergency departments to image the humerus. In the United States humeral fractures represent 4% to 5% of all fractures.¹ Corby described fracture patterns in the humerus as being about the same regardless of age; however, older patients with osteoporosis are more susceptible to these types of fractures.¹ The mechanism of injury can be either a disease process or trauma, and a pathologic fracture can be as challenging to image as a fracture caused by a fall on an outstretched arm. Additionally, severe trauma such as a gunshot wound to the arm can be enormously challenging for the radiographer (see Figure 1).

Regardless of the mechanism of injury, several projections have been described to help radiographers image humeral fractures. These include the anteroposterior (AP), commonly referred to as external rotation; lateral or internal rotation; axillary; scapular "Y"; and transthoracic projections of the shoulder. Each of these projections has been described in radiographic positioning textbooks²⁻⁴ and should be a part of a seasoned radiographer's repertoire.

The AP is relatively easy to perform and frequently requires placing the imaging receptor (IR) diagonally to ensure inclusion of both joints. In a true AP of the humerus, the epicondyles of the distal humerus are placed equidistant from the IR, and the central ray (CR) is directed to the mid-diaphysis of the humerus. The lateral projec-

tion is performed in the same manner, but the arm is internally rotated, placing the epicondyles of the distal humerus perpendicular to the IR. The advantage of these 2 methods is that they can be performed with the patient either recumbent

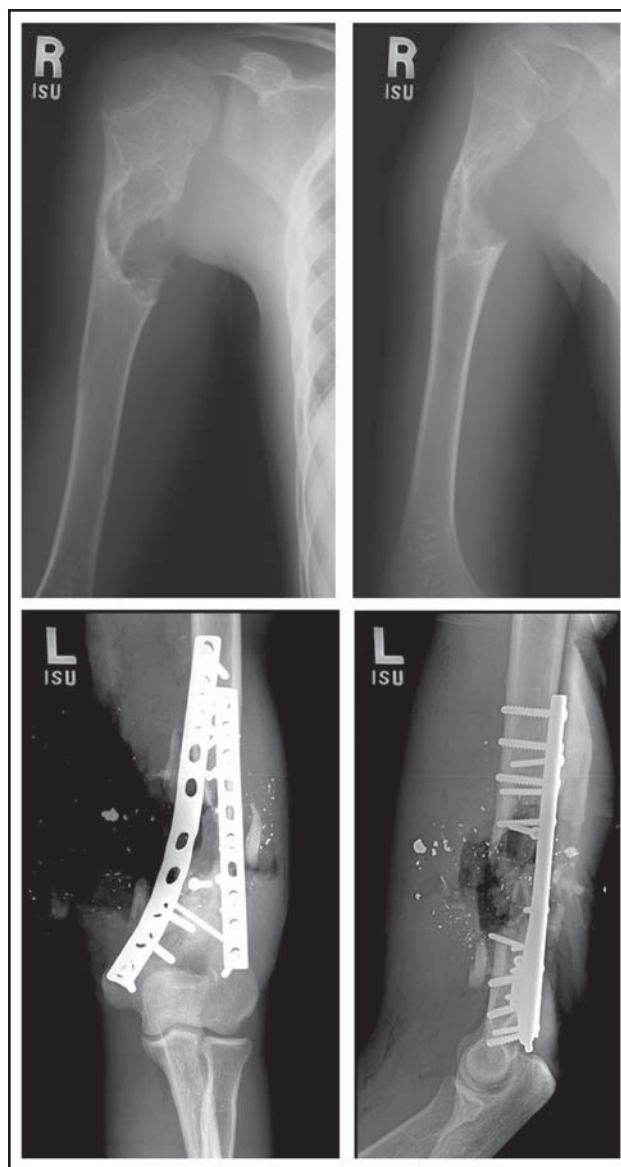


Figure 1. Nonossifying fibroma (top) and gunshot wound to the humerus (bottom). The images at the top demonstrate a nonossifying fibroma, a pathological disease process that can cause humeral fractures. The images on the bottom demonstrate a gunshot wound that has been repaired.

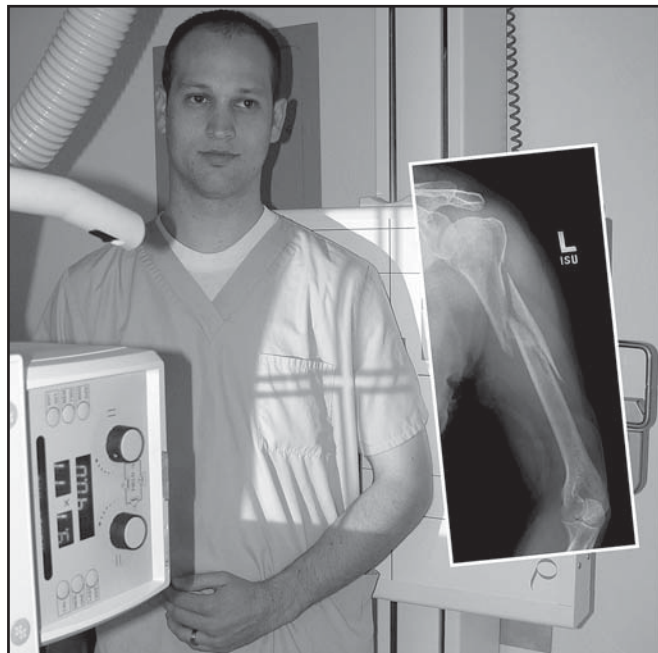

Figure 2. Standing AP projection with a slight 20° to 25° left posterior oblique position and resulting radiograph. This position can be performed either sitting or standing, as demonstrated here.

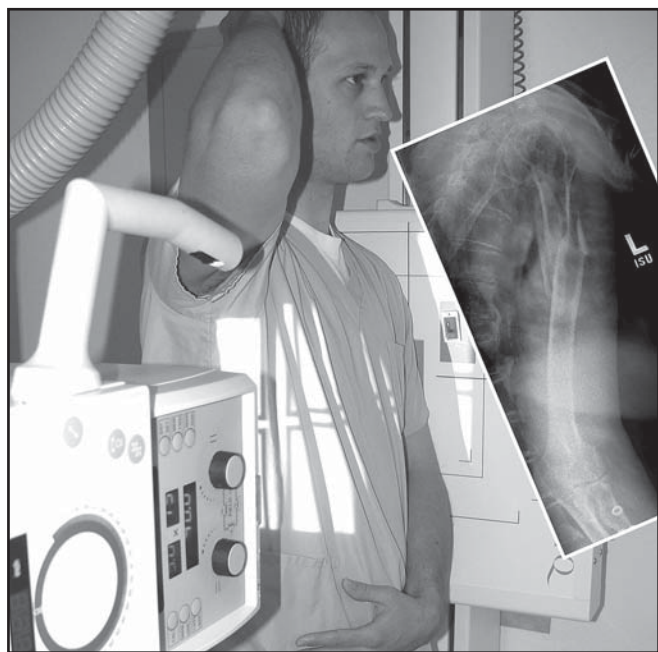

Figure 3. Standing transthoracic/transabdominal projection of the humerus and resulting radiograph. The patient is positioned laterally with the unaffected arm raised above the head. This position is 90° from the AP projection and can be performed sitting or recumbent.

or erect. The disadvantage is that both projections are reserved for ambulatory patients because the humerus must be internally and externally rotated to obtain the desired results.

The axillary, scapular “Y” and transthoracic projections conventionally have been reserved for evaluating the proximal joint and can be used for either the lateral or internal rotational positions of this joint. The disadvantage of these projections is that they sometimes necessitate making an additional exposure to evaluate the distal humerus. This projection usually includes a horizontal beam lateral of the distal portion of the humerus. Several authors²⁻⁴ described the horizontal beam lateral by explaining that the IR should be placed between the patient’s body and the distal humerus by advancing it into the axilla.

All of the positions described above are valuable and help the physician assess the extent of injury. Radiographers should be familiar with these routine methods. Occasionally, however, an exam of the humerus will be requested on an arm that cannot be abducted. In this case it becomes increasingly difficult to image the distal portion of the arm.

Basic Positioning Principle

One of the principles taught in basic positioning classes is that radiographers always should obtain a minimum of 2 projections 90° from each other. When a patient presents with an immobilized arm that is held tightly to the body, internal and external rotational movements of the arm are inappropriate. Likewise, rotational or horizontal beam lateral projections with the IR placed next to the body, which require abducting the arm, also are ill advised.

Even when the patient’s arm is immobilized, 2 projections 90° from each other still should be taken. This requires an AP in a neutral position and a transthoracic/transabdominal projection. In this article, the latter projection will be referred to as a transthoracic projection, with the assumption that the entire humerus will be included on the study. This projection is useful to determine gross fracture alignment. In the past it was difficult to image the entire humerus with a transthoracic approach because of technique limitations. However, digital radiography has helped alleviate some of the difficulties with analog techniques by making it easier to demonstrate areas with different tissue densities. In either scenario, the radiographer must proceed with caution.

Examination Precautions

Patients who have humeral fractures frequently present to the radiology department in a sitting position. The natural traction of the arm in this position helps alleviate the pain caused by a fracture. However, the transthoracic projection also can be performed recumbent on a stretcher or x-ray table if the patient presents in a recumbent position. The severely injured patient should be radiographed in the easiest position for the patient, especially if the fracture is obvious. Care should be exercised during the transfer to a stool, if a transfer is needed. If the patient has been sedated, do not perform this exam unassisted or with the patient standing. Use vigilance to avoid a mishap and consider performing the exam recumbent. If the arm is secured to the body, leave it in the secured position.

Methods

AP Without Arm Rotation

For the erect AP projection, rotate the patient's body into a slight 20° to 25° posterior oblique position. This oblique orientation, toward the affected arm, is an attempt to achieve a more conventional AP. The oblique is not advised if the exam is performed recumbent because it would require the patient to roll onto the fractured arm. At any rate, this should not be a major concern when performing the exam recumbent. Regardless of obliquity, the CR is directed to the mid-diaphysis. In all probability, the epicondyles of the distal humerus will be approximately 45° in relationship to the IR in this position. This exam typically requires a 14 x 17-inch IR for an adult patient, which will allow imaging of both joints (see Figure 2).

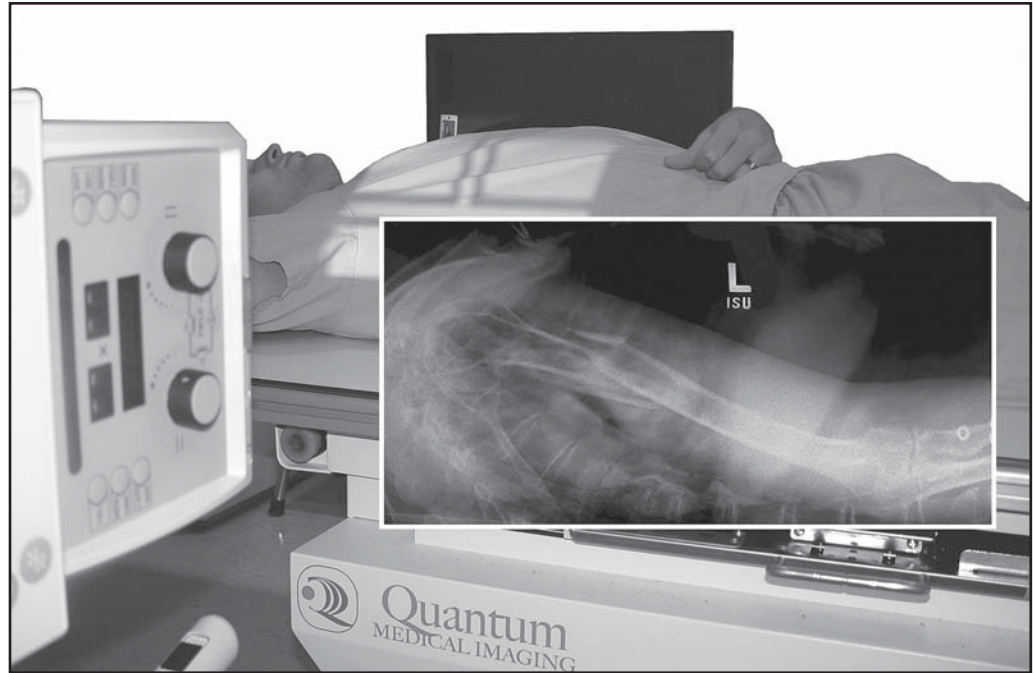


Figure 4. Recumbent transthoracic/transabdominal projection of the humerus with resulting radiograph. The patient is positioned in a similar manner to the erect position, but a horizontal beam is used.

Transthoracic Projection of the Humerus

If the exam is performed erect, rotate the patient to the lateral position with the affected side against the Bucky (see Figure 3). A cross-table approach is necessary if the exam is performed recumbent (see Figure 4). Next, raise the unaffected arm and rest it over the patient's head. If possible, move the affected arm slightly anteriorly to avoid superimposition of the humerus on the thoracolumbar spine. Direct the CR to the mid-diaphysis of the affected humerus. Ensure that the patient is in a true lateral position. This should be 90° from the AP position described previously. If the patient is able to cooperate, a breathing technique is preferable.

Discussion

The AP projection of the humerus should demonstrate the entire bony anatomy, including the glenoid cavity proximally. The epicondyles of the distal humerus also should be visualized, including at least 1½ inches distal to the elbow joint. Similarly, the transthoracic projection of the humerus should demonstrate the entire bony anatomy of the humerus superimposed on the thorax and abdominal cavities. The entire

humerus, including the proximal and distal portions, should be visualized.

The 2 projections discussed in this article demonstrate adaptations of traditional humeral projections. The difference is that the transthoracic projection is used to demonstrate the entire humerus – hence, the name transthoracic/transabdominal approach. This projection is an adaptation of the transthoracic lateral projection of the shoulder described by previous authors.²⁻⁴ The projection is useful for evaluating gross fracture alignment, can be performed in the recumbent or erect position and does not require movement of the affected arm. Also, it is now easier to obtain a better technique with newer digital technology because of the ability to postprocess the image by adjusting the contrast and density.

Perhaps these positions will come to mind the next time you are asked to obtain a radiograph of an obviously fractured humerus. ♦

References

1. Corboy D. Fractures, humerus. eMedicine Web site. www.emedicine.com/emerg/topic199.htm. Accessed May 14, 2007.
2. Bontrager KW, Lampignano JP. *Textbook of Radiographic Positioning and Related Anatomy*. 6th ed. St Louis, MO: Mosby-Year Book Inc; 2005:176-178.
3. Greathouse JS. *Delmar's Radiographic Positioning Procedures*. Albany, NY: Delmar Publishers; 1998:156-162.
4. Frank ED, Long BW, Smith BJ. *Merrill's Atlas of Radiographic Positions and Radiologic Procedures*. 11th ed. St Louis, MO: Mosby-Year Book Inc; 2007:159-163.