

Chest Radiography for Radiologic Technologists

DAN L. HOBBS, M.S.R.S., R.T.(R)(CT)(MR)

The chest exam is performed more frequently than any other exam in the imaging department. It is important for radiographers to understand the standards for imaging the chest because good chest radiographs are critical in managing patient care. This article provides an overview of chest radiography from the perspective of both the radiologist and the technologist. Readers will gain an understanding of several pathologic processes involving the chest and can use this information to perform optimal radiographic imaging.

This article is a Directed Reading. Your access to Directed Reading quizzes for continuing education credit is determined by your area of interest. For access to other quizzes, go to www.asrt.org/store.

After completing this article, the reader should be able to:

- Identify the basic anatomy seen on a chest radiograph.
- Describe the anatomical relationships of various organs in the chest.
- Describe the basic positioning requirements for a chest exam.
- List the criteria used to critique a chest radiograph.
- Identify radiologists' requirements for interpreting a chest radiograph.
- Discuss several common disease processes of the lungs and their radiographic appearances.
- Evaluate a chest radiograph for various devices such as endotracheal tubes, chest tubes and central venous catheters.
- Describe several pathologies of the chest.

Chest radiography is the most common radiographic procedure performed in medical imaging departments, and one of the most often repeated exams.¹⁻³ It is estimated that in the United States 68 million chest radiographs are performed each year.⁴ Chest radiography is performed to evaluate the lungs, heart and thoracic viscera. Additionally, disease processes such as pneumonia, heart failure, pleurisy and lung cancer are common indications. The American College of Radiology (ACR) and others suggest that daily chest radiographs are indicated for critically ill patients.⁵⁻⁷ This includes patients on ventilators, as well as those with acute cardiopulmonary problems. According to the ACR Practice Guidelines for the Performance of Pediatric and Adult Chest Radiography, there are several indications for a chest radiograph.⁵ Some of these indications include:

- Evaluation of signs and symptoms potentially related to the respiratory, cardiovascular and upper gastrointestinal systems, as well as the

musculoskeletal system of the thorax. The chest radiograph also can help to evaluate thoracic disease processes, including systemic and extrathoracic diseases that secondarily involve the chest. Because the lungs are a frequent site of metastases, chest radiography can be useful in staging extrathoracic, as well as thoracic, neoplasms.

- Follow-up of known thoracic disease processes to assess improvement, resolution or progression.
- Monitoring of patients with life-support devices and patients who have undergone cardiac or thoracic surgery or other interventional procedures.
- Compliance with government regulations that mandate chest radiography. Examples include surveillance posteroanterior chest radiographs for active tuberculosis or occupational lung disease or exposures and other surveillance studies required by public health law.
- Preoperative radiographic evaluation when cardiac or respiratory

symptoms are present or when there is significant potential for thoracic pathology that could compromise the surgical result or lead to increased perioperative morbidity or mortality.⁵

The radiographer's role is to provide the physician with an image of the chest that is diagnostic and aids in the treatment of the patient. This cannot be accomplished satisfactorily without adequate knowledge of chest anatomy, pathology and consistent positioning in both the ambulatory and bedridden patient.

Normal Chest Anatomy

The Bony Thorax

The bony thorax of the chest is composed of the sternum anteriorly and 12 pairs of ribs that surround the lungs. Each pair of ribs connects to a corresponding thoracic vertebra posteriorly. The posterior rib attachments connect at the costovertebral and costotransverse joints. Each rib wraps around the lung and descends approximately 3 to 5 inches from its highest point posteriorly.² (See Figure 1.) The anterior portion of each rib connects by way of costocartilage to the sternum. The costocartilage usually does not show up on a radiograph unless it is calcified. The true ribs, numbers 1 through 7, connect anteriorly to the sternum by way of this costocartilage. (See Figure 2) The false ribs are numbers 8 through 12. Ribs 8 through 10 connect to the sternum by way of the costocartilages of the seventh ribs. False ribs 11 and 12 are short and do not wrap around the body; they also are called floating ribs. The ribs collectively provide a protective framework for the lungs.

The Respiratory System

The respiratory system is composed of the larynx, trachea, bronchi and lungs. The larynx, commonly referred to as the voice box, is the most superior structure in the respiratory system and houses the vocal cords. In close proximity to the larynx are the thyroid cartilage, laryngeal prominence or Adam's apple, and the cricoid cartilage. The epiglottis also is located nearby and acts as a covering for the trachea when food is swallowed. The trachea descends inferiorly beginning at about the level of C5 to approximately T5 or T6, where it bifurcates at the carina into the right and left primary bronchi. The bronchi then subdivide into several branches. Three secondary branches feed the right lung and 2 secondary branches feed the left lung. These branches divide into tertiary levels and smaller segments, eventually ending in the terminal bronchioles where the alveoli exchange oxygen and carbon dioxide.²

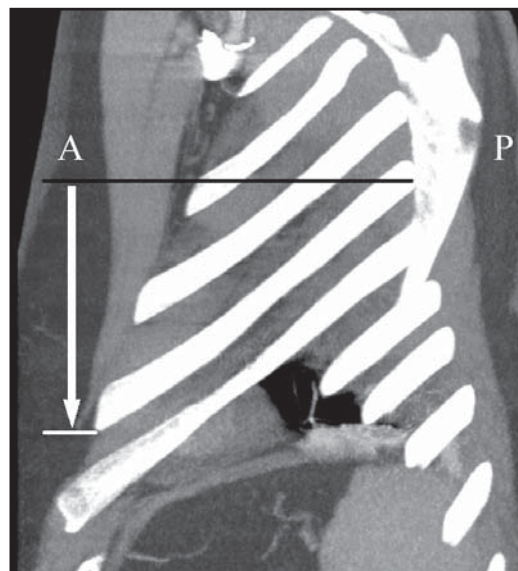


Figure 1. Sagittal CT image of the chest. This reformatted image demonstrates the posterior (P) to anterior (A) descent of the ribs as they wrap around the body. The distance between the 2 lines represented by the arrow is approximately 3 to 5 inches in most individuals.

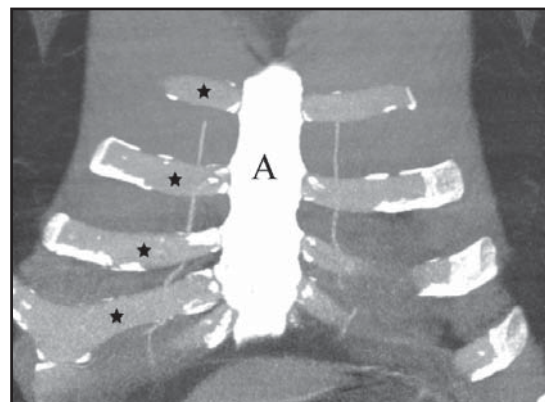


Figure 2. Coronal CT image of the anterior chest. This reformatted image of the anterior chest demonstrates the sternum (A). The stars indicate a few of the anterior ribs, which are composed of costocartilage. The anterior ribs do not visualize on chest radiographs unless they are calcified. Note the calcifications that have formed on the proximal and distal segments of the costocartilages in this example.

The Lungs

The lungs are composed of a spongy material called the parenchyma. The parenchymal tissue contains the fine structures of the bronchial trees and pulmonary circulation. The exchange of oxygen and carbon dioxide takes

place at the alveolar level within the parenchyma. There are millions of alveolar sacs within each lung. Daniels and Orgeig stated that “in humans there are ~25 branches and 300 million alveoli. This structure allows for the generation of an enormous respiratory surface area (up to 70 m² in adult humans).”⁸

The alveoli are composed of 2 types of cells, identified as Type I and Type II cells. Daniels and Orgeig defined the purpose of each of these cell types as follows:

- Type I cells are the main constituent of the walls of each alveolus.
- Type II cells secrete surfactant,⁸ which reduces surface tension, thus reducing the tendency of the alveolar sacs to collapse.⁹

The pulmonary arteries and veins supply blood to all portions of the lungs. This network surrounds the alveoli, where oxygen and carbon dioxide are exchanged with the blood.² (See Figure 3.)

Divisions of the Lungs

Structurally, the right lung is composed of 3 lobes. They are named according to location as the upper, middle and lower lobes. The upper and middle lobes are separated by a fissure called the horizontal fissure. Occasionally, this fissure shows as a lucent line on a radiograph. An additional oblique fissure separates the middle and lower lobes.

The left lung is composed of 2 lobes — a superior and inferior lobe divided by an oblique fissure. The lung parenchyma superior to each clavicle is called the apical portion of the lung. This area is often the hiding place for pulmonary nodules and can be hard to evaluate because of the overlying anatomy of the clavicles. Radiographers use the lordotic position to visualize this area.

Inferiorly, the lateral lung angles are in close proximity to the ribs. These angles are named after their location: hence the term costophrenic angles. (See Figure 4.) The right and left costophrenic angles are important radiographically because they can be used to detect effusions and other abnormalities. When this happens, they appear flattened or blunted as a result of fluid buildup or retention.

Diaphragm

The diaphragm is a muscular structure located immediately below the lung bases. Though it is a single organ, it is divided into 2 sections called the right and

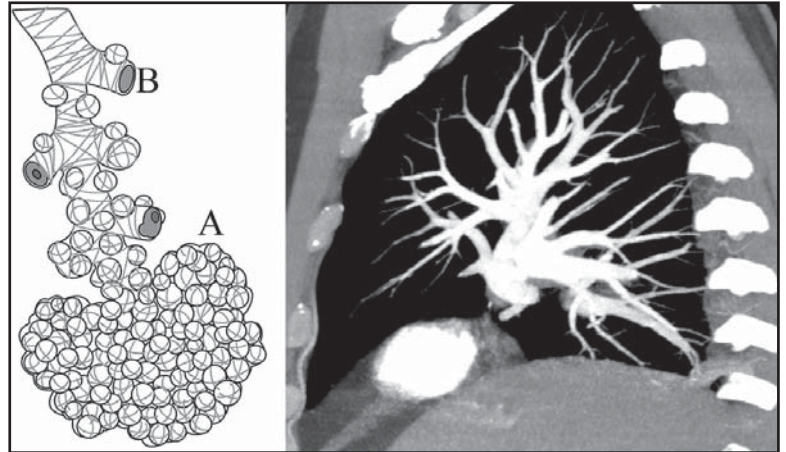


Figure 3. Sagittal CT image of the chest (right). This reformatted image demonstrates the pulmonary arterial circulation opacified with contrast media. The main branches of the bronchioles lie in close proximity to this arterial circulation. The line drawing on the left depicts the bronchiole (B) and alveolar (A) levels within the parenchyma. These structures are the most distal features of the bronchiole tree.

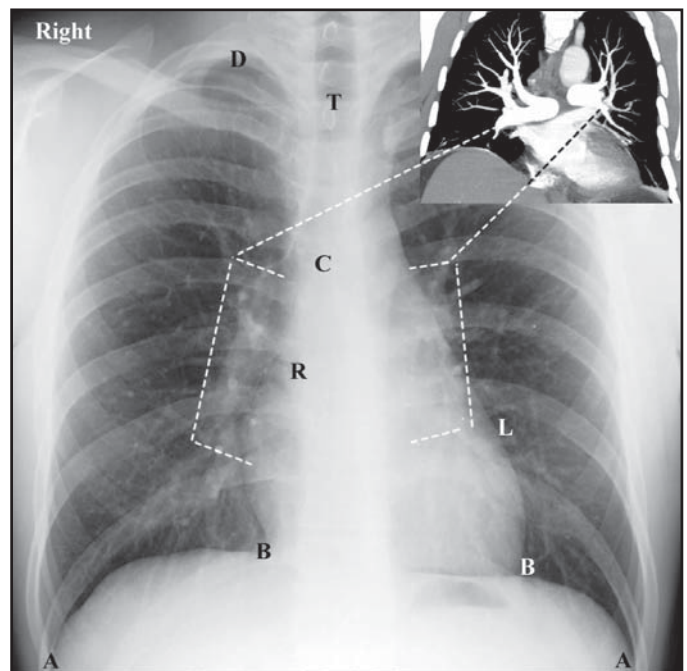


Figure 4. Coronal CT image and a chest radiograph. The costophrenic angles (A) should be visualized on all chest radiographs. B represents the right and left cardiophrenic angles, C the carina, R the right atrium, L the border of the left ventricle, T the trachea, D the right apex. Additionally, the dotted lines identify the area of the hila of the chest.

left hemidiaphragms. The right hemidiaphragm is higher on a chest radiograph because of the location of the liver, which is immediately inferior to it. The term cardiophrenic angles is sometimes used to describe the area where the heart's border comes in contact with the diaphragm. There are both right and left cardiophrenic angles, which should be visualized on a normal chest radiograph. (See Figure 4.)

Pleura

Each lung is surrounded by a thin-walled sac called the pleura. The pleura completely encases the lung with an inner layer called the pulmonary or visceral layer and an outer layer called the parietal layer. The potential space between these 2 layers is called the pleural space. Radiographically, this space is important because it can fill with air (pneumothorax) or blood (hemothorax), which can be seen on a chest radiograph. A chest tube can be placed within the pleural space to drain accumulated fluid or air.

The Mediastinum

The mediastinum is the space between the lungs that houses the heart and great vessels, including the proximal pulmonary arteries and aortic root. Additionally, the proximal bronchial trees, pulmonary veins, a portion of the esophagus and lymphatic vessels are important structures found in the mediastinum. The hilum "is the central area of each lung, where the bronchi, blood vessels, lymph vessels and nerves enter and leave the lungs."² (See Figure 4.) Furthermore, the thymus gland is located above the heart in the superior mediastinal compartment.

Patient Preparation for the Chest Exam

All Patients

Prior to proceeding with the exam, all women of child-bearing age should be asked if there is any possibility of pregnancy. The ACR guidelines⁵ suggest that all imaging facilities should have policies and procedures in place that identify patients who might be pregnant prior to exposing them with ionizing radiation. Additionally, clothing that interferes with the exam should be

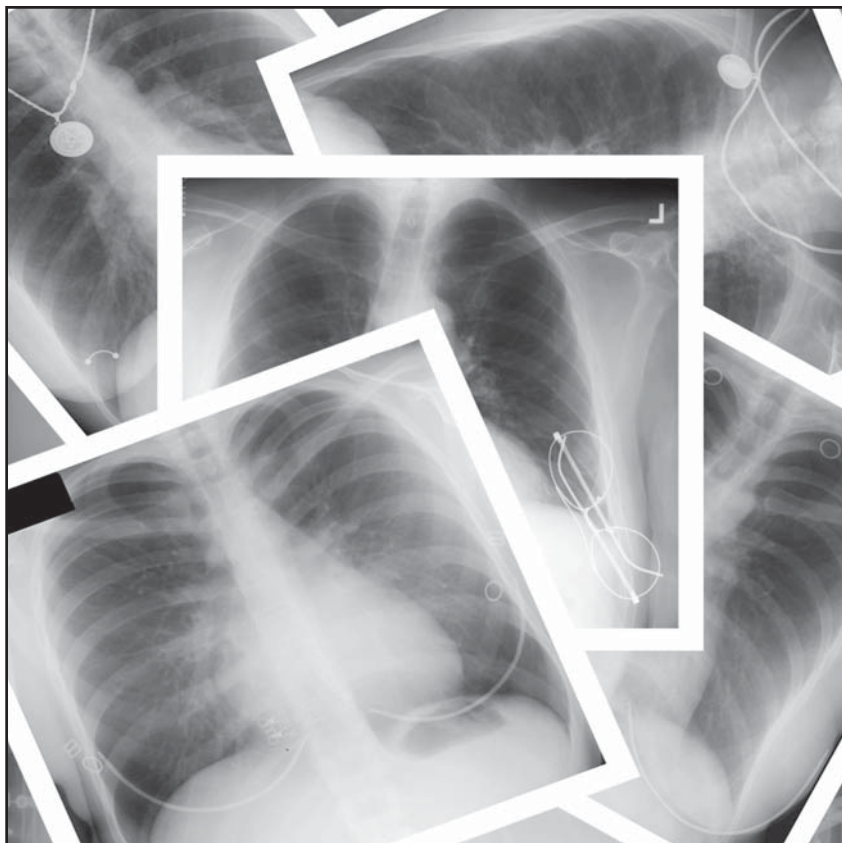


Figure 5. Radiographic collage of the chest. Each of these images required repeat exposures due to carelessness in screening patients for artifacts.

removed. This includes items such as bras, jewelry, buttons or any metal objects that could interfere with the study.⁵ T-shirts with prominent logos also should be removed because they can show up on the study and can interfere with the diagnosis. Long hair that is in braids or tightly held together with rubber bands should be moved from the upper lung fields.² Figure 5 shows several artifacts that resulted in repeat radiographs.

Body piercings and especially nipple piercings are common metallic foreign bodies that can interfere with interpretation and diagnosis. This can be a delicate and embarrassing subject for patients. The question should be phrased sensitively to avoid offending the patient. It is not appropriate to ask a patient if he or she has a nipple piercing. However, simply inquiring if all metal has been removed from the chest area is appropriate. Some body piercings have been welded closed and cannot be removed unless cut. Likewise, some patients will not remove a body piercing because piercings can be difficult or impossible

to reinsert. In fact, the Association of Professional Piercers on its Web site stated, "Even momentary removal of jewelry from a healing piercing can result in amazingly rapid closure of the piercing and make reinsertion difficult or impossible."¹⁰ This site also claimed that metal piercings will not interfere with or obstruct the visibility of pathology on a thoracic radiograph. The decision to remove a piercing should rest with the patient. However, the radiographer should explain that the patient might be asked to remove the piercing on subsequent radiographs if it does indeed interfere with a diagnosis. The choice to do this would still rest with the patient.

Inpatients and Portable Exam Preparation

Part of preparing a patient for the exam includes removing irrelevant material from the area of interest. Radiographers performing inpatient chest exams in the radiology department and portable chest exams throughout the hospital should be particularly aware of this. Extra time should be taken to ensure that external tubes and lines are redirected from the imaging area. Inpatient gowns frequently contain snaps that can interfere with the study. Sometimes these gowns can be removed and replaced with snapless gowns. If not, the snaps should be repositioned away from the field of view. Likewise, oxygen tubing, electrocardiogram (ECG) leads, the external portions of nasogastric tubes, enteral feeding tubes, temporary pacemakers and telemetry devices should be directed to an appropriate area outside of the collimated field. Care should be taken to avoid disconnecting or inadvertently extracting these devices. Figure 6 demonstrates how distracting they can be if not removed from the field of view. Time should be taken to move these items because they interfere with the visibility of pertinent anatomy. When they remain in the field of view they diminish the quality of the exam, resulting in poor patient care and sometimes missed diagnoses.

Radiography of the Chest

Conventional radiography of the chest has been described in several positioning textbooks.^{2,11} The basic radiographs include a posteroanterior (PA) projection and lateral position. For acutely ill patients, an anteroposterior projection (AP) often is obtained. If the patient is in the emergency room (ER) or intensive care unit (ICU), AP portable chest radiography usually is performed. It is interesting to note that it has been estimated that in many medical centers up to 50% of chest radiographs are performed with a portable x-ray machine.¹² AP projections obtained with portable units

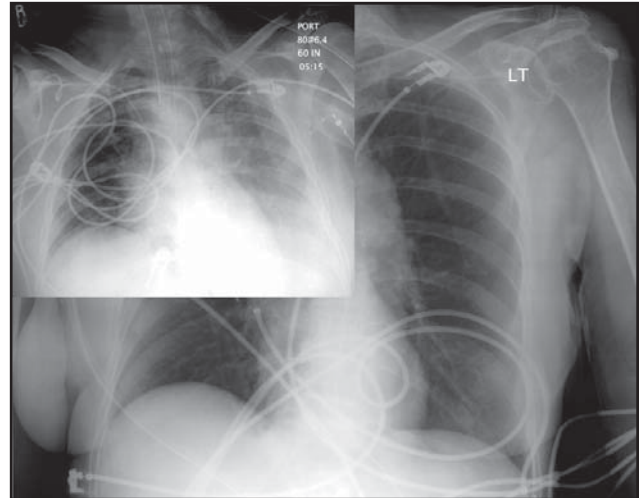


Figure 6. Radiographs demonstrating extraneous tubes and lines. These 2 radiographs demonstrate poorly placed ECG lines that interfere with the chest exam. The lines should have been redirected from the field of view prior to making an exposure.

have several disadvantages compared with PA projections. These include magnification of the heart and thoracic viscera, inability to obtain adequate inspiration because of difficulty obtaining the study erect and technique variations caused by inadequate placement of grids and screens.

Several authors have suggested that chest radiography should be performed with a 72-inch source-to-image-receptor distance (SID) to reduce magnification of the heart.^{2,11} Some medical centers use a 120-inch SID for this reason. Quite often, an erect view is difficult to obtain when performing chest radiography because of the patient's condition. However, erect studies are preferred because they better demonstrate pleural effusions and pulmonary edema. Furthermore, when the patient is in an erect position the abdominal structures descend, allowing the patient to take in a deeper breath. This results in a better radiograph, with the lung parenchyma better visualized.

The PA Projection

The PA is performed by positioning the patient against the upright Bucky. (See Figure 7.) First, adequate radiation protection should be provided to the patient whenever possible. This means that the radiographer should provide a wraparound apron or other shielding devices as deemed appropriate. Next, the patient should stand in a relaxed position facing the Bucky with the shoulders

rolled forward. Rolling the shoulders forward is important because it moves the scapular bodies from the lung fields, allowing for better visualization of parenchymal anatomy. The head should be extended slightly to avoid cranial anatomy overlying the apical portion of the lungs. The placement of the cassette should be about 2 inches above the patient's shoulders. When using older film-screen technology this allows for placement of the patient identification (ID) block outside of the lung anatomy. With newer computed radiography (CR) equipment, placement of the ID block is of less concern because it is not used for ID purposes. With CR equipment this block is used to orient the image as it is being read by the CR reader. Proper placement will result in an image display on the computer monitor that is correctly oriented. Neither of these issues are a concern with a direct radiography (DR) system because cassettes have been replaced with permanent imaging plates. Regardless of whether older analog systems or newer digital technology is used, Bucky height is critical to preclude clipping anatomy; thus, adequate placement is about 2 inches above the shoulders.

Bontrager² described an interesting method of positioning for the PA chest exam, known as the hand-spread method. He recommended that prior to using this method the radiographer should measure his or her own thumb-to-little-finger distance. Sometimes it is also beneficial to measure the distance between the index finger and thumb. Once these distances are known, the measurements can be used to align the patient's midlung field with the center of the imaging receptor (IR). To accomplish this, the radiographer places the tip of his or her small finger on the vertebra prominens (C7) while extending the thumb inferiorly along the spinous processes. (See Figure 7,

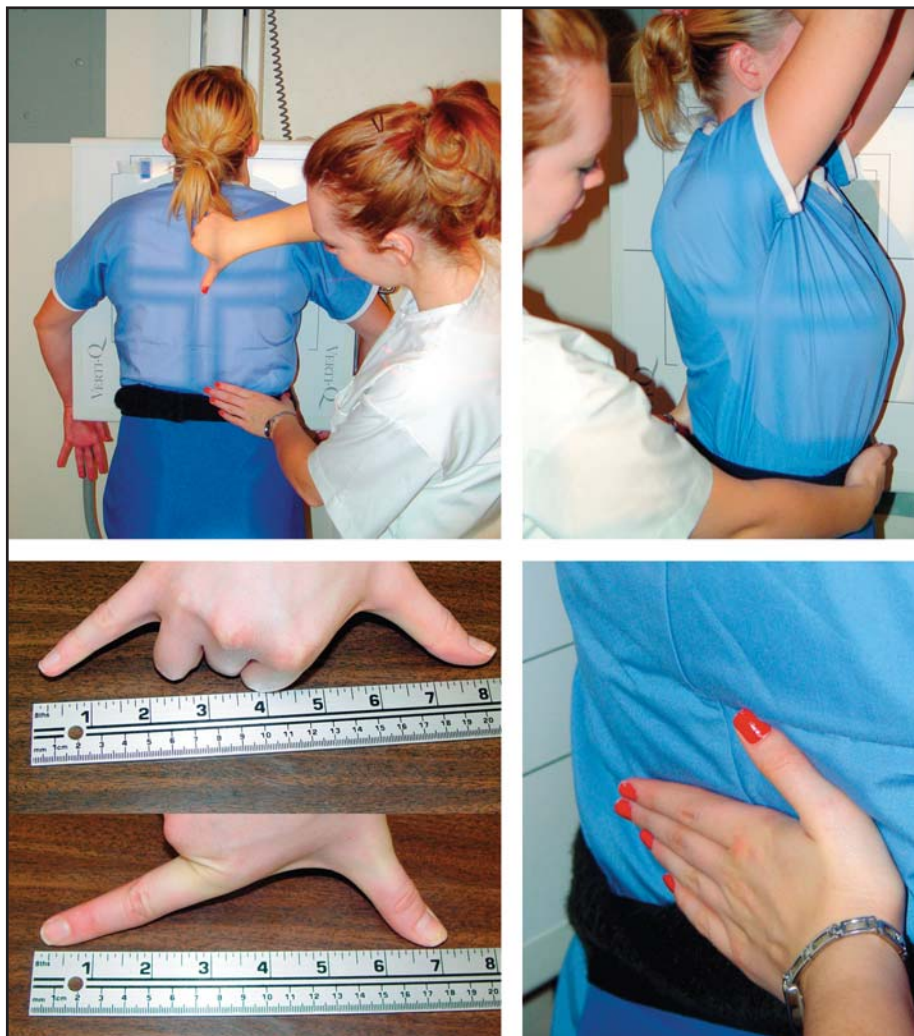

Figure 7. Positioning for the PA and lateral projections of the chest. Upper left: a radiographer uses the hand-spread method to center the radiograph to T7. Upper right: Positioning for the lateral projection of the chest. Lower left: Measuring the thumb-to-little-finger and index-finger-to-thumb distances. These measurements can be used to determine the centering for a properly positioned PA projection of the chest, which is 7 inches for the average woman and 8 inches for the average man.² Lower right: avoiding a rotated lateral projection by using the hand to feel the rib cage.

upper left image.) Likewise, the index finger and the thumb also could be used. The middle of the chest correlates to T7, which is located 7 inches inferior to the vertebra prominens for most women and 8 inches inferior for most men. The central ray is then placed at this level. This distance can vary slightly depending on variations in body habitus, but it generally holds true for most patients. For example, Bontrager² noted that well-developed athletes with a sthenic or hyposthenic body

habitus often require centering between 8 and 9 inches from the vertebra prominens. Conversely, a patient with a hypersthenic body habitus should be centered between 6 and 7 inches from the vertebra prominens.

Next, the top of the collimated light field is put at the level of the vertebra prominens. This corresponds to the level of the pulmonary apices. Because of the divergent nature of the x-ray beam, when the upper collimated beam reaches the IR all of the apices will be included on the radiograph, thus precluding clipping important thoracic anatomy. Likewise, by using this method the collimation at the bottom of the radiograph includes the lung bases, thus providing equal collimation at the top and bottom of the IR. This is an interesting method and with practice can result in better-centered radiographs of the chest.

The exposure is made with high kVp, high mA and short exposure time. The patient should be instructed to hold his or her breath on the second inspiration. This allows for a better inspiratory effort and, as a consequence, a radiograph with fully inflated lungs.

The Lateral Position

The lateral radiograph of the chest is performed by placing the left hemithorax against the IR. The arms should be raised above the head. Occasionally, an intravenous (IV) pole or other support can be used to help maintain this position. The left lateral position is routine because it places the heart closer to the IR.

The shoulder is in close contact with the IR superiorly; however, depending on body habitus, this often results in greater object-film distance inferiorly. This can be as much as 2 or 3 inches. Care should be taken to ensure that the patient is standing straight and that the body does not tilt toward the IR. It is tempting for new radiographers to tilt the patient to reduce the object-film distance. However, this is incorrect and should be avoided because the radiograph will appear distorted. Tilt "may be evident by closed disk spaces of thoracic vertebrae" on the radiograph.²

To ensure that the patient is standing in a true lateral position, some radiographers place a hand on the patient's lower back, where the ribs are easy to palpate. The radiographer can ensure superimposition of the right and left rib cages by rotating the patient if necessary while feeling the posterior ribs. When the radiographer's hand is perpendicular to the IR, unwanted rotation generally is eliminated. (See Figure 7, lower right image.) Again, the exposure is made with high kVp, high mA and short exposure time. As in the

PA projection, the exposure is made upon the second inspiration.

The Portable AP

The portable exam is performed whenever the patient cannot come to the department for traditional PA and lateral radiographs of the chest. Sometimes a portable chest radiograph can be performed only with the patient in the supine position. Whenever possible, however, it should be performed with the patient erect or erect "to the greatest angle tolerated by the patient."¹¹ Patients who are on ventilators or have had recent surgery present a challenge when trying to position for the AP, and the examination often must be performed with the patient supine. As stated previously, care should be taken to reposition ECG wires and tubes overlying the chest that interfere with physician interpretation. Radiographers always should keep this in mind because portable studies are performed on critical patients who present with all sorts of paraphernalia.

Semi-erect films often appear lordotic when performed with the portable x-ray machine. This happens when the x-ray tube and IR are not properly aligned. The x-ray tube should be perpendicular to the IR to avoid a lordotic appearance. However, if fluid levels are a concern, the x-ray tube should remain in a horizontal position. In this scenario, to avoid a lordotic appearance, a decubitus position should be considered. These decisions are made by the radiographer and are paramount in providing good patient care. This means that the radiographer should evaluate the reason for the chest radiograph and then determine the best method to use. For example, if the exam was ordered to demonstrate possible pleural effusions, it should be performed with the patient fully erect with a horizontal beam. If the patient's condition does not allow for an erect examination, a lateral decubitus projection provides similar information. On the other hand, if the portable exam is ordered to demonstrate a line placement and the patient presents in a semi-erect position, the x-ray tube should be tilted caudally to avoid a lordotic appearance. This generally places the x-ray tube at a 90° angle to the IR. Other factors such as the placement of grids and screens require additional forethought on the radiographer's part.

Consistency in Positioning

It is not unusual for patients in the ICU to have portable chest radiography performed daily. In these scenarios, similar positions should be employed each

day. This means that radiographers making these exposures should check previous radiographs to ensure they are providing uniformity in positioning and technique. Subtle changes often are noted on daily radiographs when they are compared with each other. Such findings could prompt changes in patients' medical treatment,^{7,13} as a study performed by Marik and Janower confirmed.¹⁴ They found that 66% of intubated patients and 25% of nonintubated patients in an ICU had modifications in treatment based on results of daily chest radiographs.

As a result, it is important that radiographers provide consistency when performing chest radiography. Subtle changes seen on chest radiographs should be the direct result of the patient's condition and not a result of variations in positioning. Consistent positioning can be accomplished only by providing adequate documentation on the radiograph. To do this, some radiology departments use a sticker to record this information. Newer digital technologies provide a way to add electronic annotations to images. At a minimum, the sticker or annotation should include the date and time of the exam, the distance used, the patient's position and the technique employed. This permits consistency when follow-up studies are performed by multiple radiographers working different shifts. Regardless of which method is employed to record this data, it is crucial that the information is retrievable in some format. It is also crucial that radiographers review this information prior to performing subsequent chest radiography.

The exposure for the AP portable chest radiograph should be made on the second inspiration if possible. For patients who are unresponsive or require mechanical ventilation by a respiratory therapist or anesthesiologist, a coordinated effort will be necessary to ensure that there is sufficient inspiration prior to making the exposure. Likewise, if the patient is on a ventilator ". . . carefully watch the patient's chest to determine the inspiratory phase for the exposure."¹¹

Technical Evaluation Of a Chest Radiograph

Once the film has been exposed and processed, the responsibility of reviewing it does not rest solely with the radiologist. The film first should be evaluated by the radiographer. In a conversation with D. Madden, M.D., (October 2006), he said "The technologist is responsible for the technical excellence of the study." This statement emphasizes the importance of obtaining a quality exam

and reinforces the fact that radiographers play an integral role in the care of patients. A radiograph cannot be interpreted adequately by the radiologist unless it is technically adequate.

The following considerations should be evaluated by the radiographer prior to submitting the radiograph for review:

- Correct demographic information.
- Correct marker placement.
- Correct exposure.
- Adequate position.
- Sufficient inspiration.
- Pertinent anatomy demonstrated.

Correct Demographic Information

This information should include the patient's name and any other identifying information deemed necessary by the institution. The ACR guidelines suggest that each image be permanently marked with the patient's name, the x-ray number or some other identifying number, the date and time the exam was performed and the patient's date of birth.⁵

Correct Marker Placement

The correct anatomical side marker, right or left, should be visible on the final radiograph. Care should be exercised by the radiographer to ensure that the marker will not interfere with interpretation by covering pertinent anatomy. Additional care should be exercised to make sure that the marker is placed on the correct side. Conditions such as situs inversus show the importance of correct marker placement. Situs inversus is a reversal of anatomy. As Wilhelm explained: "In situs inversus, the morphologic right atrium is on the left and the morphologic left atrium is on the right. The normal pulmonary anatomy is reversed so that the left lung has 3 lobes and the right 2 lobes. In addition, the liver and gallbladder are located on the left, while the spleen and stomach are located on the right. The remaining structures also are a mirror image of the normal."¹⁵

Markers are often color coded, which helps to reduce errors. Nonetheless, radiographers always should check prior to making an exposure to ensure that the correct marker is placed on the correct side. Writing "R" or "L" on the radiograph after the exposure is generally not acceptable because of legal issues associated with mismarkings.² This also could hold true for annotating an image after exposure with newer digital technologies.

Correct Exposure

Evaluation of the radiograph for the correct exposure is vital. An underexposed radiograph that is too light may simulate pulmonary opacities that are not really present, leading to a false positive result. Likewise, an overexposed film that is too dark or overpenetrated can burn out essential anatomy. An example would be a pulmonary nodule that was not seen because of overexposure, resulting in a false negative interpretation.¹⁶ Digital technology is solving these types of concerns. Digital images can be manipulated after processing by the user. Changes to density and contrast can be made after the exposure by adjusting the window and level of the image. Therefore, anatomy that cannot be adequately visualized can be manipulated by the operator to enhance the image. Conventional analog techniques do not allow for this type of manipulation.

Regardless of the type of imaging equipment used, adequate exposure is evaluated by visualizing the thoracic vertebrae behind the heart. On a correctly exposed radiograph, the vertebrae and corresponding posterior ribs should be faintly visible through the heart. Bontrager stated, "A determining factor for this on PA chest radiographs is to be able to see faint outlines of at least the mid and upper vertebrae and posterior ribs through the heart and other mediastinal structure shadows."² Additionally, the pulmonary blood vessels should be visualized out to the distal third of the peripheral lung field.¹⁶

Adequate Position

Prior to submitting a radiograph for interpretation, the radiographer should confirm that an adequate position was obtained. This means that the radiograph should not show signs of rotation. If the patient was properly positioned for the frontal projection, a term that often is used by radiologists in place of AP or PA, the medial ends of the clavicles will appear equidistant from the spinous processes of the thoracic vertebrae.² (See Figure 8.) Variation of more than 1 cm could affect the appearance of the lung.¹⁷ This is important because rotation can cause differences in density. Likewise, certain conditions such as mediastinal widening cannot be evaluated properly on a rotated chest radiograph.¹⁸ Additionally, on a well-positioned chest radiograph the scapulae should not be seen in the lung field. Scapular densities can prevent detection of abnormalities in the periphery of the lung.

Proper positioning on a lateral chest radiograph

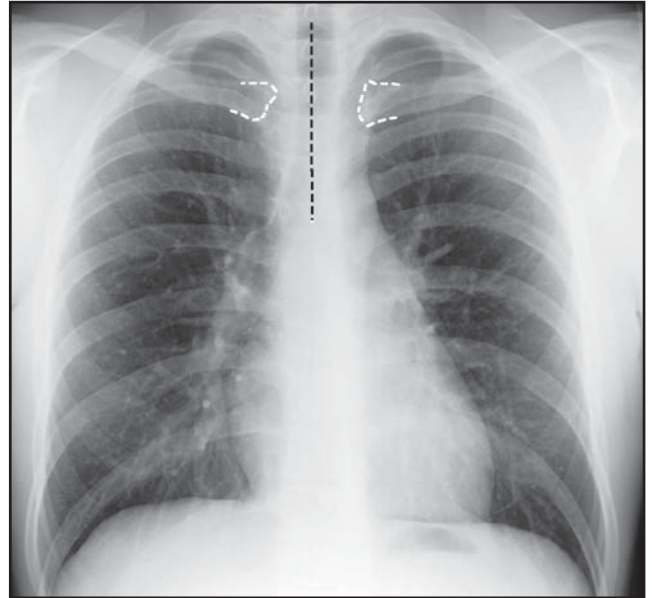


Figure 8. PA chest radiograph demonstrating no rotation. The white dotted lines on this radiograph outline the sternal ends of the clavicles, which should be equidistant from the spinous processes of the thoracic vertebrae, represented by the black dotted line.

should demonstrate superimposition of the ribs posteriorly. Generally, rotation of no more than a quarter to a half inch is acceptable.² (See Figure 9.) Likewise, the patient's arms should be lifted high enough to avoid superimposition of the soft tissues of the arms on the upper apices. The sternum should be visualized as a thin bony structure on the anterior thorax. If it appears widened, this is another indication of rotation.

Sufficient Inspiration

Sufficient inspiration is evaluated by visualizing 10 posterior ribs above the diaphragm on a frontal projection of the chest.^{2,11} (See Figure 10.) Radiographers may wonder why it is important to have good inspiration on a chest radiograph. Alben¹⁷ explained that if the patient does not provide an adequate inspiration, the lung markings become crowded and the radiologist could interpret an abnormality that is not really there. Likewise, the heart shadow and borders are not adequately visualized without adequate inspiration. Alben also noted that "the heart will appear larger than it actually is."¹⁷ Bontrager² and Ballinger¹¹ both persuasively explained the importance of exposing on the second breath hold, which generally provides a deeper inspiration.

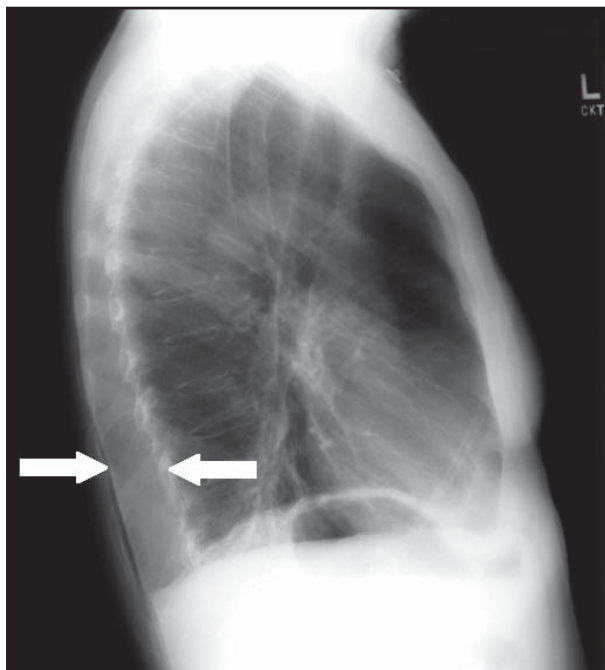


Figure 9. Lateral chest radiograph demonstrating rotation. No more than one-quarter to one-half inch rotation is acceptable for a lateral projection of the chest.

Pertinent Anatomy Demonstrated

The chest radiograph should demonstrate all of the anatomy of the lungs from the apices to the lung bases. (See Figure 10.) This means that both hemidiaphragms should be seen in their entirety. Student radiographers often question how close the costophrenic angles can be clipped without requiring a repeat. In response, an experienced radiographer might explain that pleural effusion is a frequent finding on chest radiographs and sometimes blunting of the costophrenic angle is the only radiographic sign. Therefore, all of the costophrenic angles should be visualized.

Densities on a Chest Radiograph

The amount of blackening on a chest radiograph is a direct result of the amount of radiation that passes through the thorax and reaches the imaging receptor. Specific terminology is used to describe the differences in tissue attenuation when this happens.¹⁹ Radiolucency describes the ability of the x-ray beam to pass through a body part. For example, the lungs are radiolucent because they are composed mainly of air, allowing for easy passage of the x-ray beam through the parenchyma. Likewise, fat

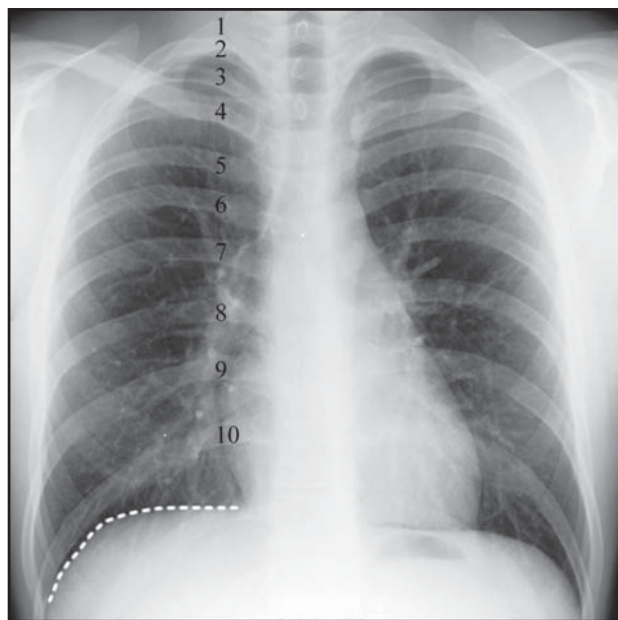


Figure 10. Radiograph demonstrating sufficient inspiration. The patient has provided sufficient inspiration on a PA projection of the chest if 10 ribs can be visualized above the diaphragm. The posterior ribs are numbered from 1 to 10 and the white dotted line represents the right hemidiaphragm. The frontal projection also should include all of the anatomy from the apices to the lung bases.

is radiolucent compared with bone, but not quite as radiolucent as air. Conversely, in comparison with the lungs, the spine is radiopaque. The term radiopaque describes how the x-ray beam is attenuated as it interacts with the calcium in the thoracic spine.¹⁹ Radiolucent structures are captured on the recording media as black or very dark shades of gray. Radiopaque structures are captured as white densities.

Additionally, the atomic number of an element determines its radiopacity. Higher atomic-numbered elements have increased radiopacity, or the ability to attenuate the x-ray beam more; therefore, these densities appear white on radiographs. See Table 1 for a list of common elements encountered in radiology and their corresponding atomic numbers. Understanding these concepts is crucial when evaluating the different densities seen on a chest radiograph.

The structures within the chest are composed of 5 basic densities. Four of these densities are inherent to the organism; the last is metal, which is man-made. Each can be evaluated on a chest radiograph. They are listed in order from the most radiolucent to the most radiopaque:

- Air.
- Fat.
- Soft tissue.
- Bone.
- Metal.

Air

Air is the most radiolucent substance visible on a radiograph. The lungs are black on a radiograph because they are filled mainly with air.

Fat

Fat by itself appears as very dark shades of gray on a radiograph. However, it can vary in appearance depending on the location, thickness and the collective effect of composite tissues. Quite often fat densities appear in the axilla on a PA radiograph of the chest as thin dark radiolucencies.

Soft Tissue

Soft tissue structures in the thorax include the heart and great vessels. These structures have a greater radiopacity than the lungs; therefore, they appear white. Likewise, if the bronchi become plugged with mucus or filled with fluid, the resulting appearance on a radiograph resembles tissues of water density, such as the heart. Radiologists commonly refer to these types of densities as “tissues of water densities” because, regardless of their composition, they are represented by various shades of white on the radiograph.

Bone

Bone is composed primarily of calcium. It is the calcium that makes the bones appear white on a radiograph. The composition of bone varies, resulting in various shades of densities on the radiograph from gray to white. For example, trabecular bone is more porous than compact bone and is represented on a radiograph with shades from gray to white. Impenetrable compact bone is represented as white. As a result, the ribs, clavicles, scapulae and vertebrae are visualized as white on a chest radiograph.

Metal

Metal is included in this discussion because it is commonly seen in the body. Metal absorbs more radiation than any of the other 4 basic densities and thus appears white on radiographs. Examples related to the chest include shoulder joint replacements; metallic sutures, such as those seen in patients who have had open heart surgery; surgical clips; pacemakers; and stents.

Table 1
Atomic Numbers of Common Elements
In the Radiographic Sciences²⁰

Element	Atomic Number
Hydrogen	1
Oxygen	8
Calcium	20
Iodine	53
Barium	56
Lead	82

Differences in Densities And Radiographic Signs

Anatomy on a chest radiograph is visible because of the different densities discussed above. For example, the left ventricle of the heart can be seen because the left lung is in close proximity to the left ventricle and the radiopacities of these 2 structures are strikingly different. Hence, the border of the heart is visible.

Occasionally, the heart border cannot be seen on a chest radiograph. This happens when the lungs, bronchioles or interstitium become full of secretions, such as blood or pus from infection, or filled with tumors. The lung then is composed of tissues that are like water densities, making it similar in density to the heart. When this happens, the border of the heart cannot be seen because the adjoining lungs now have the same density. According to Siela, “If 2 structures of equal density are adjacent to each other, the border of neither structure can be detected.”²¹ This is called the silhouette sign. This sign is very helpful and often used by radiologists to evaluate disease processes of the thorax.

Example of the Silhouette Sign

When a pathologist microscopically views a tissue sample from a normal lung and then compares it with a tissue sample from an abnormal lung that is full of fluid, they appear drastically different. (See Figure 11.) This holds true of their radiographic appearances, as well. Air-filled alveoli appear black, and fluid-filled alveoli appear white on a radiograph. As Chandrasekhar explained, “Most of the disease states replace air from alveoli with a pathological process, which usually is a liquid density and appears white.”²² Radiologists use radiographic signs such as this to help them identify

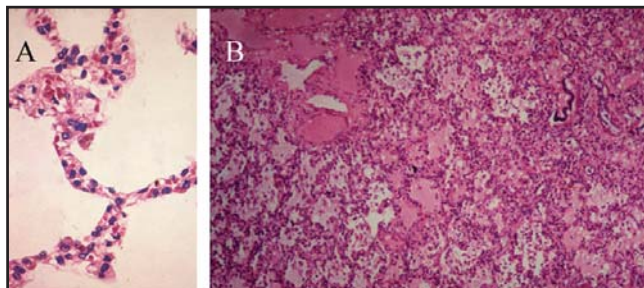


Figure 11. Microscopic images of air- and fluid-filled alveoli. A. Normal lung showing alveoli filled with air. B. Abnormal lung with fluid-filled alveoli, such as would be seen in a patient who has pulmonary edema. (Image courtesy of Arcot J. Chandrasekhar, M.D., MBBS, FACP, FCCP, FRCP(C), professor of medicine, Pulmonary Critical Care Division, Loyola University, Chicago, IL.)

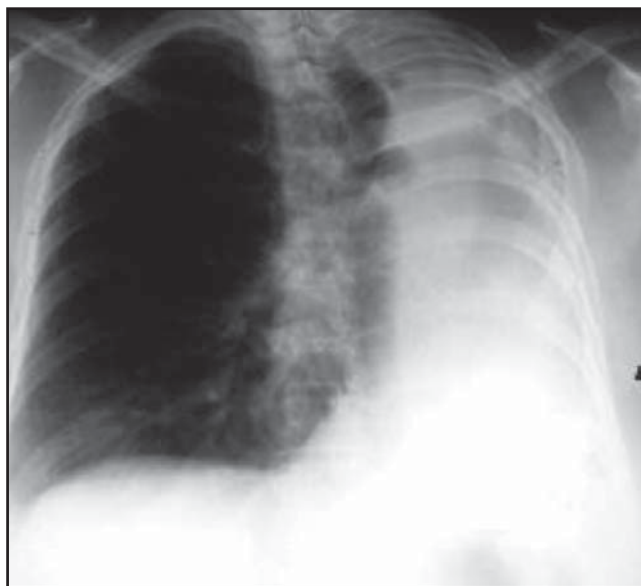

Figure 12. Radiograph of the chest demonstrating a left pneumonectomy. The heart is undetectable because fibrous tissue has filled the space once occupied by the left lung. The heart and this tissue are of the same density; hence, the heart's border is invisible. This is an example of the silhouette sign. (Reprinted with permission from W. Herring, Albert Einstein Medical Center, Philadelphia, PA. LearningRadiology.com Web site. www.learningradiology.com.)

specific disease processes on chest radiographs. For example, Herring²³ described a patient who had the left lung removed. (See Figure 12.) The area where the lung once was located has filled in with fibrous tissue. The heart cannot be seen because the adjacent fibrous tissue is of equal density.

Systematic Approach To Viewing Radiographs

To ensure that pathology is not missed when interpreting studies, radiologists often use a systematic approach. This is vital for radiographers to understand because it helps ensure continuity of care when radiographers appreciate what the interpreting physician is evaluating. Dick²⁴ explained what a physician looks at when reviewing a chest radiograph. She wrote that initially the radiograph should be reviewed by looking at the technical aspects. These include checking the position to verify if it was AP, PA, supine or erect, as well as assessing the image for rotation, technique and overall appearance of soft-tissue structures. This is accomplished by evaluating the sternal ends of the clavicles and the visibility of the thoracic vertebrae behind the heart. Gender often can be determined by the presence of breast shadows. Consequently, it may be during the technical evaluation that a mastectomy is discovered.

After the technical components have been reviewed, the radiograph should be systematically evaluated. Several authors have suggested different ways to do this.^{17,21,24-25} However, the method listed by Dick²⁴ seems comprehensive. She suggests beginning by looking closely at the mediastinal contours. She accomplishes this by running her eyes down the left side of the radiograph and then up the right side. While performing this she checks for anatomical structures such as the trachea and great vessels of the heart and lungs. The trachea should be in the upper central area of the image. The arch of the aorta is seen inferior to the trachea and is the first structure located on the left side of the spine when glancing inferiorly from the trachea. Inferior to the arch is the left pulmonary artery. She then suggests looking for the branches of the pulmonary arteries as they fan out to the periphery of the lungs.

The heart should be positioned with two-thirds of it on the left side of the chest and one-third on the right. It should take up no more than one-half of the thoracic cavity at its widest point. Additionally, the left border of the heart is composed of the left atrium superiorly and the left ventricle inferiorly. On a chest radiograph, the right border of the heart is composed of the right atrium alone. This is interesting because on a PA radiograph of the chest the right ventricle sits anteriorly; therefore, it does not have a visible border. Moving superiorly from the right heart border, the location of the superior vena cava can be observed.

At the level of the left and right hila, the pulmonary arteries and main stem bronchi arise. This is a common site for enlarged lymph nodes and primary tumors. If

they are present, the hilum will appear bulky. Dick then suggests studying the lungs apart from the pulmonary arteries and veins. They should appear black because they are full of air. It is important to scan both of the lungs. She accomplishes this by starting at the apices and moving inferiorly, comparing the left and right lungs at the same level. Furthermore, she emphasizes the importance of looking at the lung tissue that extends behind the heart. Additionally, when comparing the periphery of the lungs to the mediastinal area, lung markings are considerably less identifiable. However, if lung markings are absent, then disease of the airspace, such as atelectasis, should be considered. Likewise, while looking in the periphery of the lung Dick suggests assessing the radiograph for a pneumothorax. If present, a distinct line will be evident on the edge of the lung field.

Finally, she reviews the surface of the hemidiaphragms. They should curve downward, and the costophrenic and cardiophrenic angles should not be blunted. If they are blunted, this suggests effusion. Air beneath the diaphragm might be noticed at this point, suggesting a perforated hollow viscus. To finish, the radiograph should be evaluated for changes in soft tissues and bony structures. A mastectomy or rib fracture can be seen when performing this step.

A similar approach can be used to evaluate the lateral chest radiograph. It is beyond the scope of this Directed Reading to discuss evaluation any further. Suffice it to say that radiographers should ensure that the technical aspects of the exam are completed appropriately so that the systematic review by the radiologist is easier to perform.

Locations of Tubes and Lines

In addition to performing adequate chest exams, radiographers should be able to recognize correct

Table 2
Location of Tubes and Lines

Tube or Line	Desired Position
ETT	Tip > 5 cm from carina
Tracheostomy tube tip	Halfway between stoma and carina
Central venous catheter	Tip in superior vena cava
PICC line	Tip in superior vena cava
Swann-Ganz catheter	Tip in proximal right or left pulmonary artery
Pleural drainage tube	Anterosuperior for pneumothorax; posteroinferior for effusion
Pacemaker	Tip at apex of right ventricle; other(s) in right atrium and/or coronary sinus
AICD	One lead in superior vena cava; other in right ventricle
NG tube	At least 10 cm of tube into the stomach
Feeding tube	Tip in the duodenum

(Reprinted with permission from William Herring M.D., Tubes and Lines: What Where and Whoops. www.learningradiology.com.)

placement of lines and tubes in the chest. Frequently, it is necessary to know where these lines and tubes are located and be familiar with their radiographic appearance. Some radiographers mistakenly believe that this could result in an ethical violation by tempting the radiographer to interpret the radiograph or provide a diagnosis. However, the Code of Ethics of the American Society of Radiologic Technologists and the American Registry of Radiologic Technologists states: "The radiologic technologist acts as an agent through observation and communication to obtain pertinent information for the physician to aid in the diagnosis and treatment of the patient and recognizes that interpretation and diagnosis are outside the scope of practice for the profession."²⁶ Providing a diagnosis is in direct conflict with the Code of Ethics and should be avoided. However, knowing the correct location of specific tubes and lines will result in better patient care by enabling the radiographer to provide correct positioning and adequate technique, both of which can be crucial in the care of the patient.

A list and description of commonly placed tubes and lines visualized on chest radiographs are shown in Table 2. They include:

- Endotracheal tube (ETT).
- Tracheostomy tube.
- Central venous catheter (CVC).

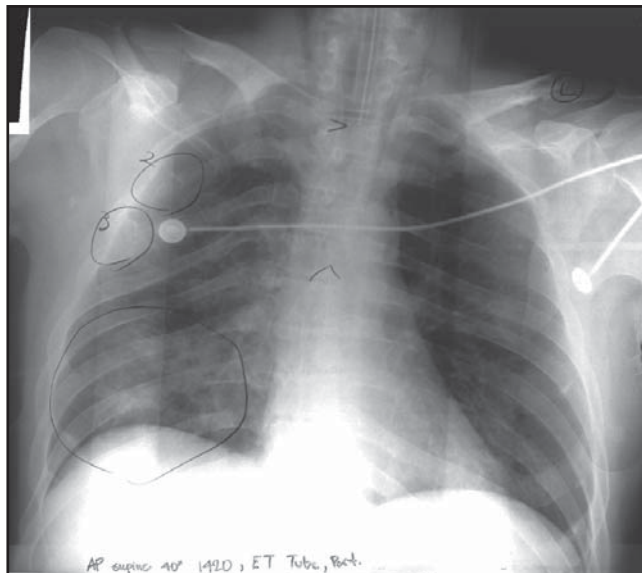


Figure 13. Radiograph demonstrating an endotracheal (ET) tube placement. A normally positioned ET tube should be located about 5 cm above the carina. The pencil mark in the center of this radiograph indicates the carina. The pencil mark at mid-T2 indicates the end of the ET tube.

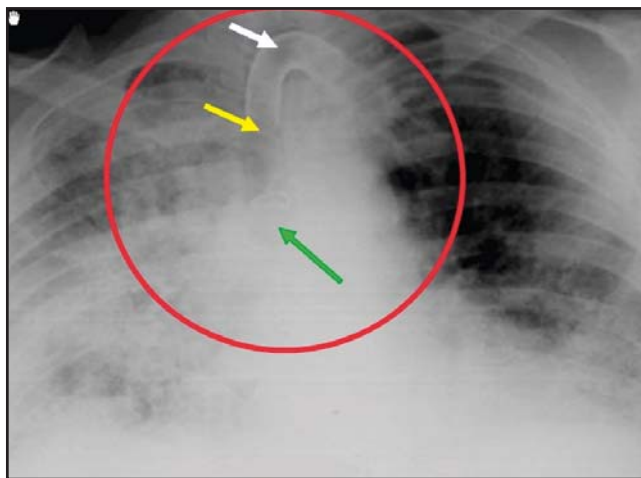


Figure 14. Radiograph demonstrating a tracheostomy tube. Herring²³ suggested that the tracheostomy tube tip (middle arrow) should be located halfway between the carina (lower arrow) and the stoma (upper arrow). (Reprinted with permission from W. Herring, Albert Einstein Medical Center, Philadelphia, PA. LearningRadiology.com Web site. www.learningradiology.com.)

- Peripherally inserted central catheter (PICC line).
- Swann-Ganz catheter.
- Pleural drainage tube.

- Pacemaker.
- Automatic implantable cardioverter defibrillator (AICD).
- Nasogastric (NG) tube.

Endotracheal Tube

An ETT is used with mechanical ventilators to manage the patient's airway. The tubes come in various sizes and are inserted more commonly through the mouth, but also can be inserted through the nose. The insertion can be made with the aid of a laryngoscope, which is a medical instrument used to guide the tube through the glottis and into the trachea. Stewart et al²⁷ suggested that correct positioning places the distal end of the tube approximately 5 cm above the carina. Portable chest radiography is a reliable method of demonstrating ETT placement, especially in ICU patients. (See Figure 13.)

Tracheostomy Tube

A tracheostomy tube is inserted in the anterior portion of the patient's neck just above the suprasternal notch directly into the trachea by an incision or by a percutaneous technique.²⁸ These patients often have undergone an ETT placement and now require longer-term ventilation. Herring suggested that the desired location of the tracheostomy tube tip on a chest radiograph is halfway between the stoma and the carina.²³ (See Figure 14.)

Central Venous Catheter

The CVC is a catheter that is placed into the subclavian, jugular or femoral vein that leads to the heart. Two types of CVCs include tunneled and nontunneled catheters. Nontunneled catheters are inserted directly into the vein for short-term venous therapy. Tunneled CVCs are inserted in the vein via a tunnel under the skin for extended access.²⁹ Some common types of CVCs are the Hickman, Broviac and Groshong catheters (Bard Access Systems Inc, Salt Lake City, Utah). A different catheter called a Port-a-Cath (Smiths Medical Inc, St. Paul, Minnesota) is a more permanent CVC usually placed under the skin in the chest that can be accessed via a Huber needle to administer medications. "A chest radiograph is the easiest way to verify central line position."²⁹ (See Figure 15.) When visualizing a CVC on a chest radiograph, the tip of the catheter should be placed in the superior vena cava just above the right atrium.³⁰ Some reasons for inserting a CVC include:

- To obtain access to the venous system when peripheral veins are not available.

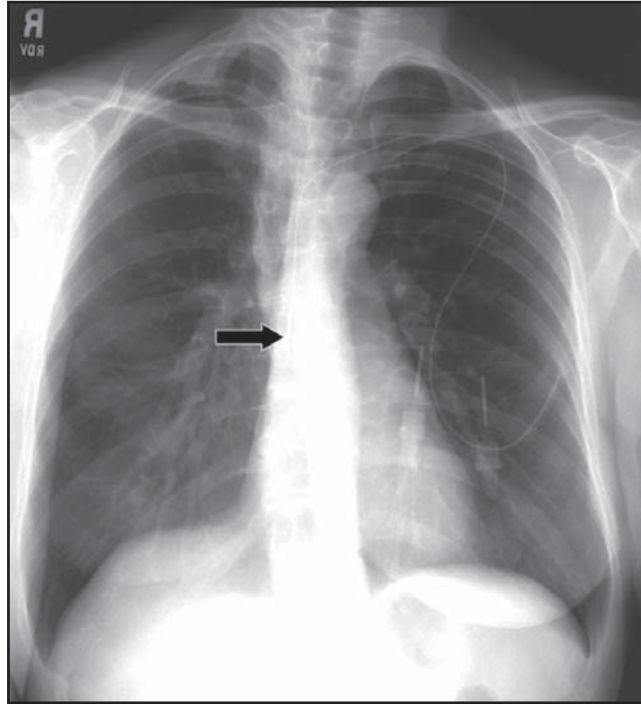


Figure 15. Radiograph demonstrating a nontunneled central venous catheter. The arrow is pointing to the tip of the CVC, which can be seen faintly in the superior vena cava just above the right atrium.

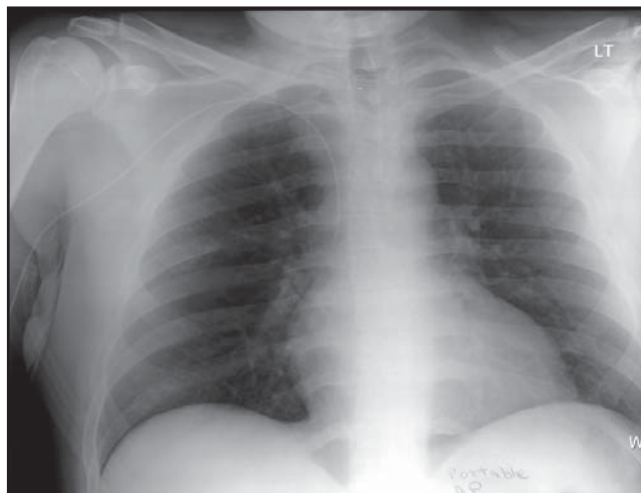


Figure 16. Radiograph demonstrating a PICC line placement. The tip of the catheter is located in the superior vena cava.

- To measure central venous pressures.
- To administer hemodialysis.
- To administer hypertonic solutions.
- To deliver parenteral nutrition.³¹

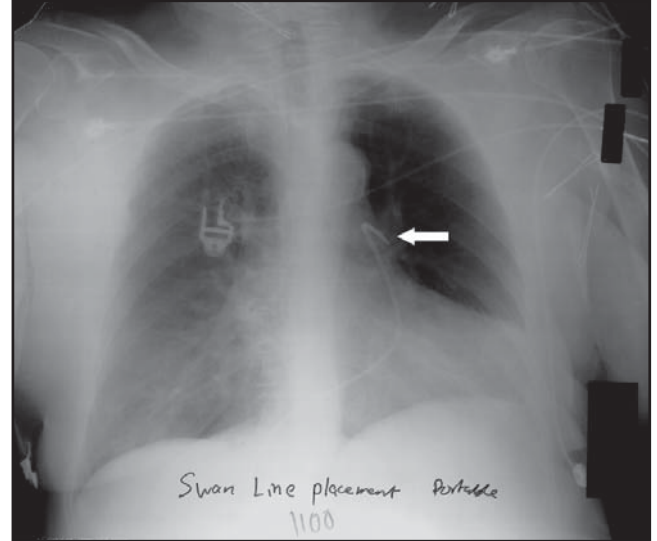


Figure 17. Radiograph demonstrating a Swann-Ganz catheter. The arrow is pointing to the tip of the catheter, which is located in the left pulmonary artery.

PICC Line

A PICC line is a CVC that is placed in a vein in the arm, such as the basilic, cephalic or brachial vein. It usually is used in patients who need extended IV access for more than a few weeks, such as those receiving chemotherapy, extended antibiotic treatment or total parenteral nutrition. The tip of the catheter is placed in the superior vena cava or proximal right atrium.³² (See Figure 16.)

Swann-Ganz Catheter

A Swann-Ganz catheter is a balloon-tipped pulmonary catheter that is passed via the internal jugular, subclavian or femoral vein through the right side of the heart into the pulmonary artery. It is used to measure the pressures in the right atrium, right ventricle or pulmonary arteries. When the balloon is inflated, the catheter can be wedged in against the wall of the left pulmonary artery. This can provide a filling pressure of the left atrium. On a chest radiograph, the catheter is located in the right or left proximal pulmonary artery.²³ (See Figure 17.)

Pleural Drainage Tube

Pleural drainage tubes often are inserted into the pleural space to remove air or fluid. The procedure is called a thoracostomy and commonly is referred to as “putting in a chest tube.” The drainage tube is inserted between the ribs into the chest cavity. A chest radiograph usually is ordered to verify location of the tube. (See Figure 18.)

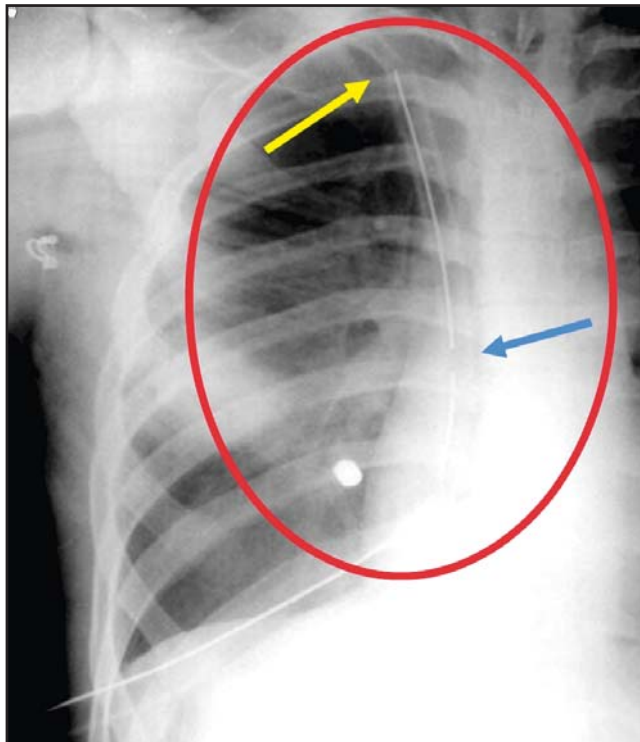


Figure 18. Radiograph demonstrating a pleural drainage tube. Herring²³ pointed out that the tip of the drainage tube (top arrow) lies in the apex of the right hemithorax. (Reprinted with permission from W. Herring, Albert Einstein Medical Center, Philadelphia, PA. LearningRadiology.com Web site. www.learningradiology.com.)

Pacemaker

The pacemaker is a medical device that stimulates the beating of the heart when the heart's natural pacemaker is not working properly. The 2 types of pacemakers commonly used are the temporary pacemaker and the permanent pacemaker. The temporary pacemaker is placed via a CVC approach, and the tip of the wire is directed to the right atrium or the right ventricle. The proximal end of the wire is connected to a small battery-powered generator located outside of the patient's body. With a permanent pacemaker, this generator is surgically implanted. It usually is implanted in the subcutaneous fat in the patient's anterior chest wall. Pacemakers can have different numbers of leads. For example, a single-lead pacemaker paces only the ventricles and a 2-lead pacemaker can pace both the ventricles and the atria.³³ (See Figure 19.)

Additionally, biventricular pacemakers can be implanted to treat patients who are experiencing heart failure.

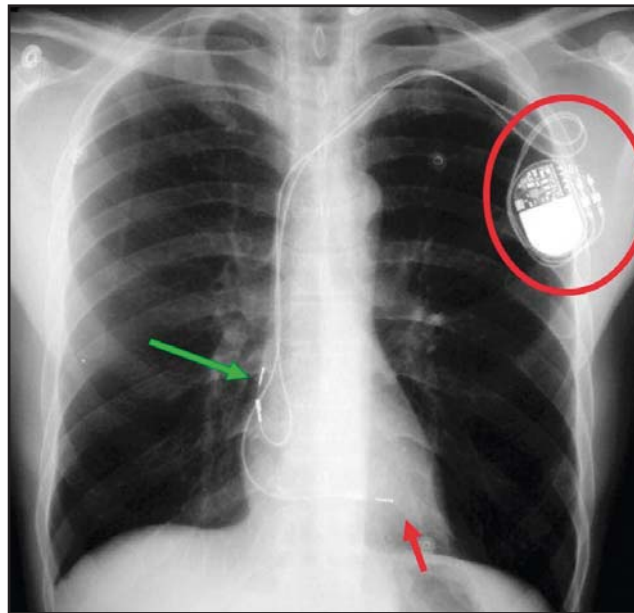


Figure 19. Radiograph showing a 2-lead pacemaker. The upper arrow points to the lead in the right atrium; the lower arrow points to the lead in the right ventricle. The generator is circled. (Reprinted with permission from W. Herring, Albert Einstein Medical Center, Philadelphia, PA. LearningRadiology.com Web site. www.learningradiology.com.)

This is called cardiac resynchronization therapy. The biventricular pacemaker allows synchronization between both sides of the heart. This pacemaker has 3 leads that are positioned in the right atrium, right ventricle and left ventricle by passing them through the coronary sinus vein.³⁴ Portable chest radiography can demonstrate the position of pacemaker leads in the heart.

Automatic Implantable Cardioverter Defibrillator

An AICD, also called an ICD, is a device that is slightly larger than a pacemaker and is implanted in the chest wall in a similar way. This device is used to detect heart arrhythmias and then deliver an electrical shock to the heart to convert it to a normal rhythm. "The lithium batteries provide a projected monitoring life of 3 years, or the capability of delivering about 100 discharges."³⁵ An AICD also can go into a pacing mode after defibrillation and act as a pacemaker if the needs of the patient warrant it. Bardy et al stated that "most cardioverter-defibrillators now require only a single lead that can be placed transvenously."³⁶ Portable chest radiography can be used to demonstrate an AICD. (See Figure 20.)

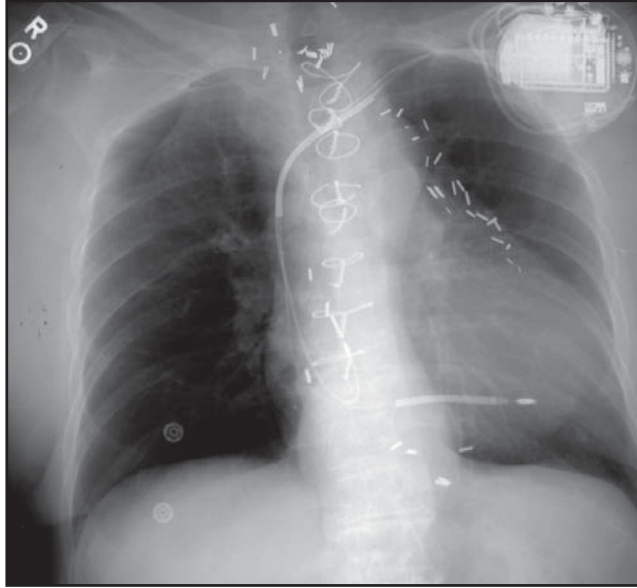


Figure 20. Radiograph demonstrating an AICD pacemaker. This is a 2-lead automatic implantable cardiac defibrillator.

Nasogastric Tube and Feeding Tube

The NG tube is a long, flexible tube that is placed through the nose into the stomach. It is included in this discussion because a chest radiograph often is ordered for NG tube placement. When this is the case, the chest should be positioned low enough to include the end of the tube or an abdominal radiograph should be suggested. An NG tube can be used to decompress the gastrointestinal tract to relieve abdominal distention. It also can be used for feeding; administering barium or medication; and lavage, such as when active bleeding or poisoning is a concern.³⁷ Kolbitsch et al³⁸ reported a case of an NG feeding tube inadvertently placed into the respiratory system in a tracheostomized patient, causing a pneumothorax. As a result of such situations, routine chest radiography is mandatory to confirm the position of NG tubes.³⁸ Herring suggested that at least 10 cm of the tube's tip should be in the stomach. Ideally, the tip should rest in the duodenum.²³ (See Figure 21.)

Common Radiographic Findings in the Chest

Radiographers should be familiar with common radiographic findings in the chest. Seven such findings are:

- Pneumonia.
- Congestive heart failure.
- Pneumothorax.
- Pleural effusion.

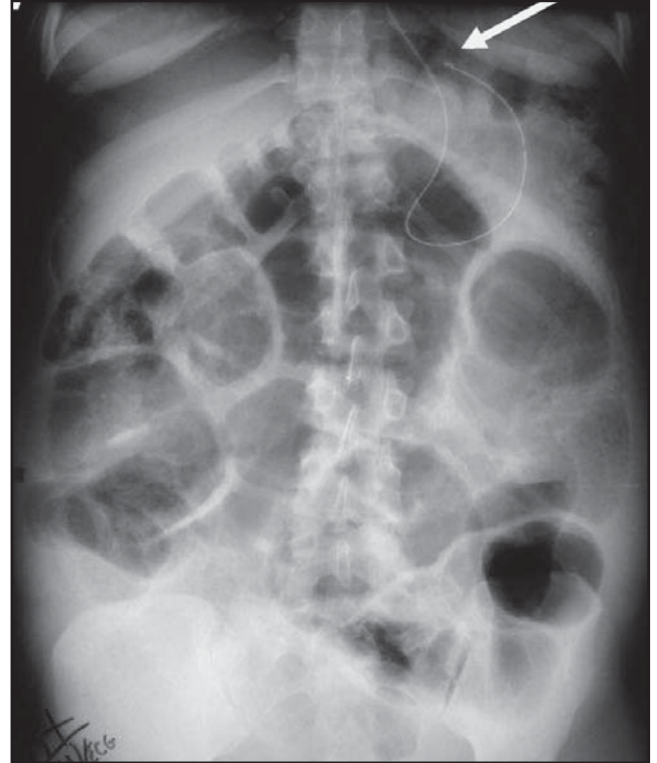


Figure 21. Radiograph demonstrating NG tube placement. Herring²³ stated that at least 10 cm of the distal portion of the NG tube should be in the stomach. The arrow is pointing to the distal tip of the tube, which has curled into the fundus of the stomach. Furthermore, when a feeding tube is placed it should be positioned in the duodenum. (Reprinted with permission from W Herring, Albert Einstein Medical Center, Philadelphia, PA. LearningRadiology.com Web site. www.learningradiology.com.)

- Cardiomegaly.
- Pneumoperitoneum.
- Emphysema.

Pneumonia

Pneumonia is an illness that shows up as a white density on a chest radiograph. (See Figure 22.) Sometimes radiologists refer to these opacities as consolidations. Consolidations occur when the lung's alveoli fill with fluid, simulating soft-tissue densities on the radiograph. There are several causes of pneumonia, including bacteria, viruses, chemicals and injury. Additionally, aspiration pneumonia can occur when the patient aspirates oral or gastric contents, such as when a stroke patient aspirates barium during a swallowing study.

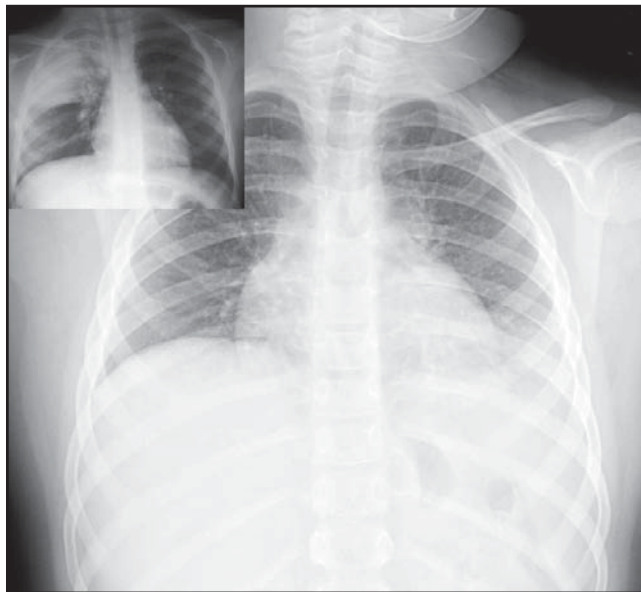


Figure 22. Radiograph demonstrating pneumonia. The larger radiograph demonstrates a left diaphragm silhouette sign. The diagnosis was a left lower lobe bacterial pneumonia. The inset radiograph demonstrates right upper lobe pneumonia. (Inset radiograph courtesy of G. Aben, Michigan State University Department of Radiology, East Lansing.)

Congestive Heart Failure

Congestive heart failure is a cardiac condition in which the heart cannot pump a sufficient amount of blood to the rest of the body. On a chest radiograph, the silhouette sign is usually obvious. Albin stated that “In most cases, heart failure is a process that occurs over time when an underlying condition damages the heart or makes it work too hard, weakening the organ.”¹⁷ The heart and the fluid surrounding the heart appear as fuzzy white densities on the chest radiograph. (See Figure 23.)

Pneumothorax

A pneumothorax is an accumulation of air in the pleural space. On a chest radiograph, this is seen as a subtle line that is usually adjacent to the rib cage. A pneumothorax can be either a unilateral or bilateral finding. It can be caused by a stab wound to the chest, chronic lung problems, biopsies and cancer, among other things. It usually is classified as either a tension or nontension pneumothorax. A tension pneumothorax is a medical emergency because it can cause a shift of the mediastinum, which can decrease cardiac output and lead to

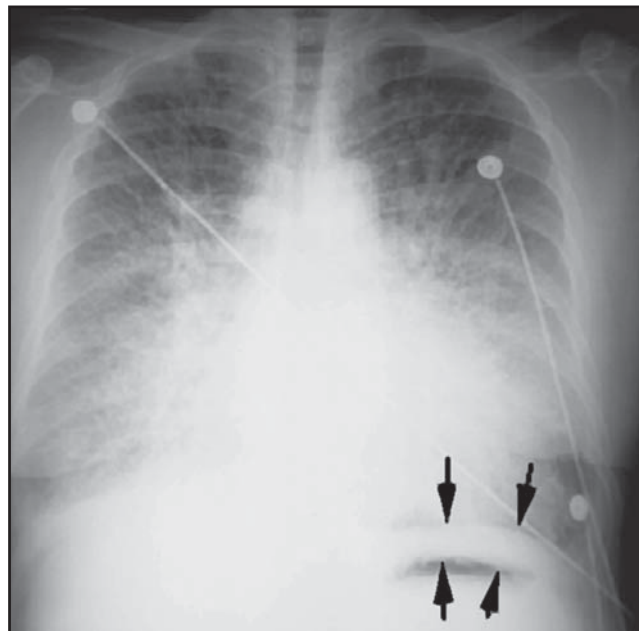


Figure 23. Radiograph demonstrating massive congestive heart failure. The silhouette sign is present. The space between the arrows in the lower portion of the radiograph is a pleural effusion. (Image courtesy of G. Aben, Michigan State University Department of Radiology, East Lansing.)

death within minutes. Frequently, a radiologist will order expiratory PA chest radiography to accentuate a pneumothorax. This visualizes well on a radiograph because the air in the pleural space remains constant while the air in the lungs decreases during the expiratory phase. This accentuates the pneumothorax by creating a distinct line on the radiograph that is formed by the interface between the soft-tissue structures of the lung and the air in the pleural space.¹⁷ (See Figure 24.)

Upright or decubitus radiography best visualizes a pneumothorax. Air rises in the chest, and in an upright position the air moves to the apices. Hence, a left lateral decubitus radiograph would accentuate a pneumothorax on the right side of the patient. In contrast, “supine AP chest radiography may not detect the presence of a small or medium pneumothorax in trauma patients.”³⁹

Pleural Effusion

A pleural effusion of the chest is an accumulation of fluid in the pleural space, such as blood, serous fluid or pus. Conditions such as congestive heart failure, pulmonary embolism, renal failure and trauma are causes. Erect chest radiography visualizes pleural effusions as blunting

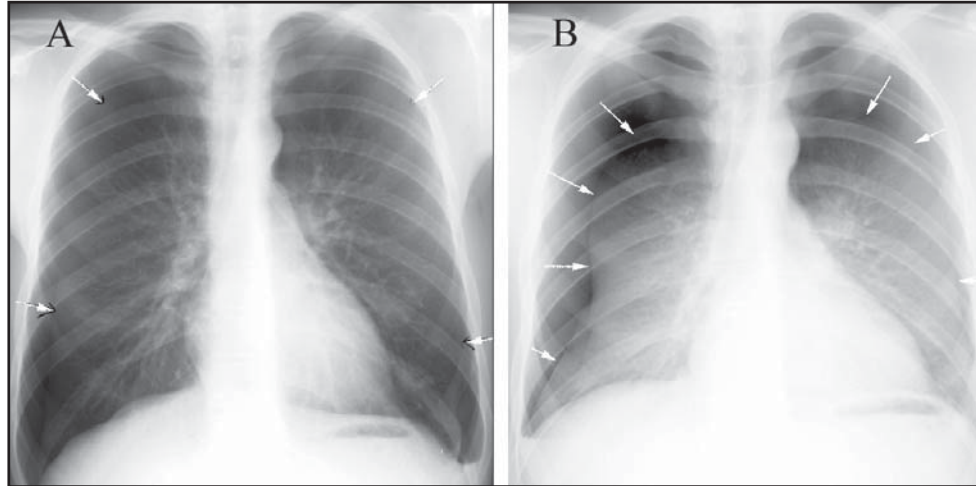


Figure 24. Radiographs demonstrating bilateral pneumothoraces. The image labeled A was taken on inspiration and shows subtle lines bilaterally (arrows) demonstrating air in the pleural space. The radiograph labeled B also shows bilateral pneumothoraces; however, the exposure was made on expiration. This decreases the lung volume, but the air in the pleural space remains the same, thus accentuating pneumothoraces. (Images courtesy of G. Aben, Michigan State University Department of Radiology, East Lansing).

of the costophrenic angles. (See Figure 25A.) This is a good argument for the necessity of including both angles when performing chest radiography. In the bedridden patient, a lateral decubitus position can be used to visualize pleural effusions. Pleural effusions are best visualized in the dependent side or side that is down. For example, if the patient is positioned in a left lateral decubitus, the fluid would descend to the dependent side, thus visualizing a left pleural effusion. (See Figure 25C.)

Cardiomegaly

Cardiomegaly is an enlarged heart, which is not a problem in and of itself; however, it is a symptom of an underlying problem.⁴⁰ (See Figure 26.) Some of the conditions that lead to cardiomegaly include high blood pressure, heart valve disorder and cardiomyopathy.⁴⁰ A radiologist evaluates the size of the heart by measuring the transverse dimension of the heart and comparing it with the transverse dimension of the thorax. "The normal heart will occupy slightly less than 50% of the transverse dimension of the thorax."¹⁷ (See Figure 27.)

Pneumoperitoneum

Air within the abdominal cavity is referred to as pneumoperitoneum. Typically, it is seen after surgical procedures; however, it also can be caused by a

perforation of the bowel or can occur spontaneously from a bowel obstruction. During trauma, a penetrating injury to the abdomen can introduce air into the peritoneal cavity. A recent report discussed a case of pneumoperitoneum caused by intercourse.⁴¹ Regardless of the cause, the air rises to the level of the diaphragms in an erect position. This black air density can be visualized on a PA chest radiograph because it comes in close contact with the white soft-tissue density of the diaphragm. (See Figure 28.)

Emphysema

Emphysema ranks as the fourth leading cause of death in the United States.⁴²

It is a disease of the lungs that often is caused by smoking. Patients who suffer from emphysema experience shortness of breath and often require oxygen therapy. Sometimes this disease is described as a chronic obstructive pulmonary disease, which also includes other diseases such as chronic bronchitis and asthma. With emphysema, the alveoli lose their elasticity and are unable to hold their shape. Patients with emphysema have a flattening appearance of the diaphragms and a barrel-shaped chest. (See Figure 29.) Gay and associates⁴³ noted that patients with emphysema often also have chronic bronchitis with associated bronchial wall thickening.

Conclusion

Chest radiography is performed thousands of times each day in the United States. Because of this frequency, radiographers sometimes become careless when performing the exam. This should be avoided because the chest exam is often critical in determining a patient's course of treatment. Radiographers play an essential role in the process, and their goal always should be to provide an image that is diagnostic and helps in the patient's overall treatment. Every patient deserves this type of care, whether in an ambulatory or inpatient setting. Quality chest radiographs cannot

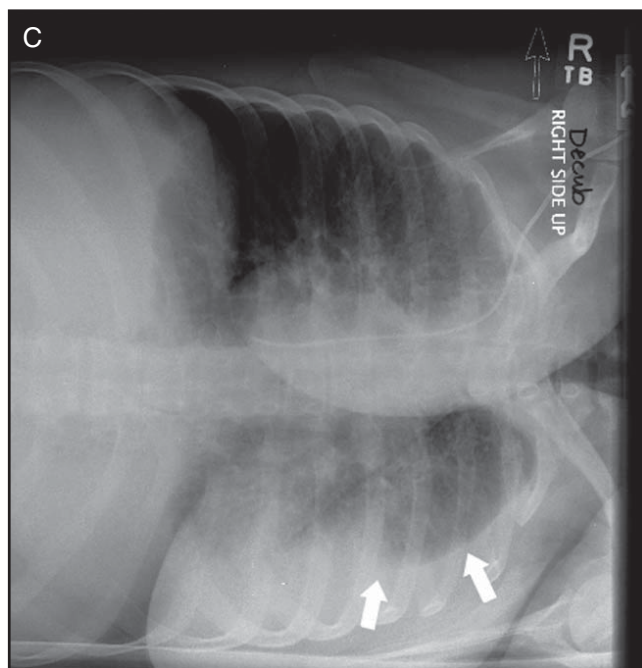
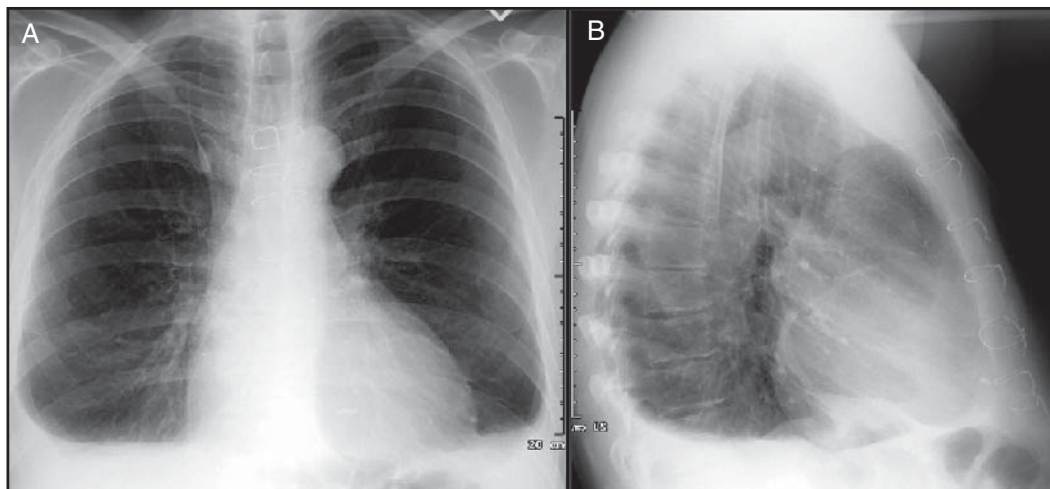


Figure 25. A. Erect PA and B. lateral chest radiographs demonstrating pleural effusion. There is bilateral blunting of both costophrenic angles. C. Left lateral decubitus chest radiograph demonstrating pleural effusion. The arrows in this radiograph demonstrate how the fluid migrates to the dependent side.

be obtained without adequate knowledge of basic chest anatomy, pathology and consistent positioning.

References

1. Radiography of the chest. The American Society of Radiologic Technologists Web site. www.asrt.org/content/thepublic/aboutradiologicprocedures/chest.aspx. Accessed October 1, 2006.
2. Bontrager KW, Lampignano JP. *Textbook of Radiographic Positioning and Related Anatomy*. 6th ed. St Louis, MO: Mosby-Year Book Inc; 2005:75-107.
3. Radiology info. ACR, RSNA Web site. www.radiologyinfo.org/en/infocfm?pg=chestrad. Accessed October 13, 2006.
4. Pelsoci TM. Low-cost manufacturing process technology for amorphous silicon detector panels: applications in digital mammography and radiography. NIST GCR 03-844, 2003;19. National Institute of Standards and Technology Web site. www.atp.nist.gov/eao/gcr03-844/gcr03-844.pdf;19. Accessed October 1, 2006.
5. American College of Radiology. ACR Practice Guideline for the Performance of Pediatric and Adult Chest Radiography. American College of Radiology Web site. www.acr.org/_s_acr/bin.asp?TrackID=&SID=1&DID=12187&CID=545&VID=2&DOC=File.pdf. Published 1995. Updated October 1, 2003. Accessed January 1, 2007.
6. Horst HM, Fagan B, Beute GH. Chest radiographs in surgical intensive care patients: a valuable "routine." *Henry Ford Hosp Med J*. 1986;34(2):84-86.
7. Henschke CI, Yankelevitz DF, Wand A, Davis SD, Shiau M. Accuracy and efficacy of chest radiography in the intensive care unit. *Radiol Clin North Am*. 1996;34(1):21-31.
8. Daniels CB, Orgeig S. Pulmonary surfactant: the key to the evolution of air breathing. *News Physiol Sc*. 2003;18(4):151-157.
9. Lloyd S. Surfactant. About: Lung Diseases Web site. <http://lungdiseases.about.com/od/glossaryofterms/g/surfactant.htm>. Accessed October 6, 2006.
10. Body piercing troubleshooting for you and your healthcare professional. The Association of Professional Piercers Web site. www.safepiercing.org/troubleshooting.html. Accessed October 13, 2006.
11. Ballinger PW, Frank ED. *Merrill's Atlas of Radiographic Positions and Radiologic Procedures*. 9th ed. St Louis, MO: Mosby-Year Book Inc; 1999:216-219, 506-539.
12. MacMahon H. Pitfalls in portable chest radiology. *Respir Care*. 1999;44:1018-1032.
13. Bransky A, Fletcher RH, Glick HA, Lanken PN, Williams SV, Kundel HL. Routine portable chest radiographs in the

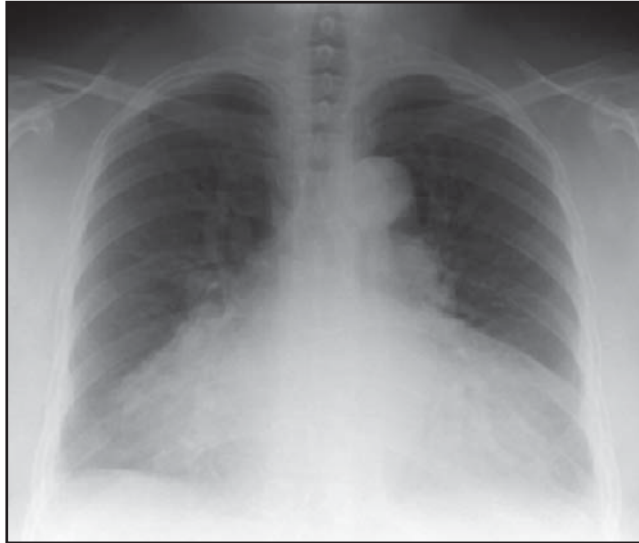

Figure 26. Radiograph demonstrating cardiomegaly. (Image courtesy of G. Aben, Michigan State University Department of Radiology, East Lansing.)

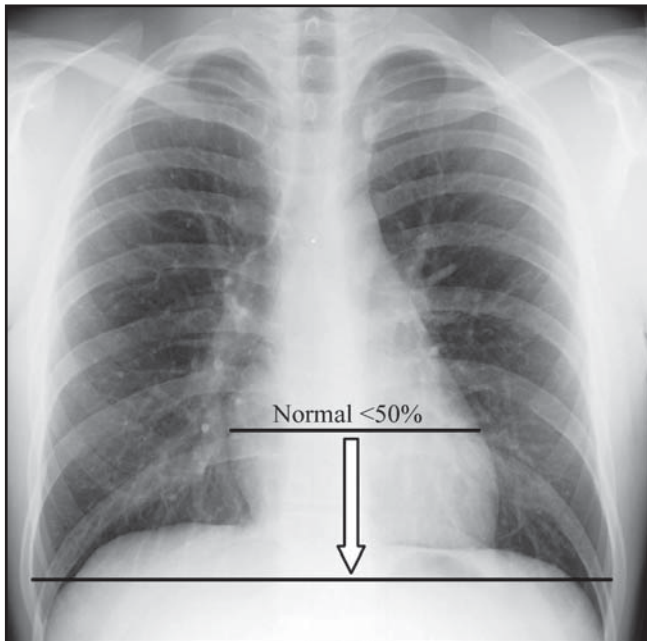


Figure 27. Radiograph demonstrating normal heart size, defined as a transverse measurement less than 50% of the thorax's transverse dimension.

medical intensive care unit: effects and costs. *Crit Care Med.* 1997;25(5):801-805.

14. Marik PE, Janower MJ. The impact of routine chest radiography on ICU management decisions: an observational

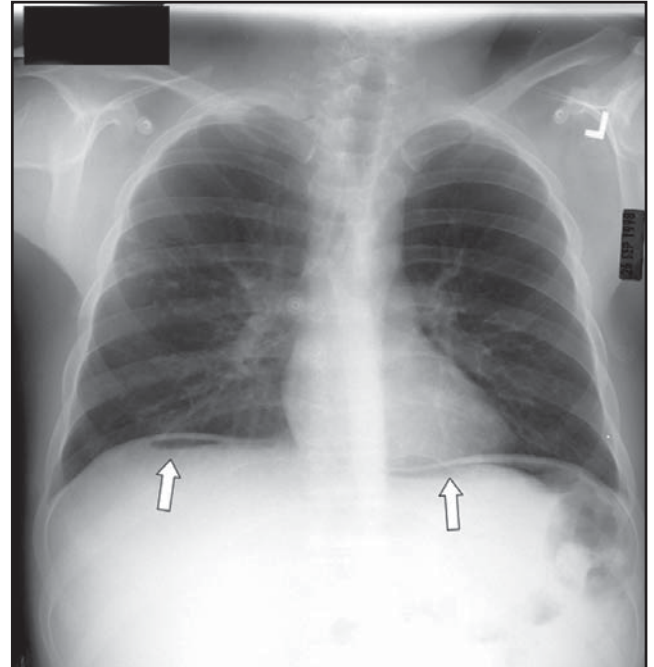


Figure 28. Upright PA chest radiograph demonstrating pneumoperitoneum. The arrows indicate black air densities bilaterally beneath the diaphragms.

study. *Am J Crit Care.* 1997;6(2):95-98.

15. Wilhelm A. Situs inversus. eMedicine Web site. www.emedicine.com/radio/topic639.htm. Accessed October 14, 2006.
16. Koenig SM. Interpretation of chest x-rays. University of Virginia Health System Web site. www.healthsystem.virginia.edu/alive/im-residency/AcuteCare/acute_060822-060824_chestxrayinterpr.doc. Accessed October 15, 2006.
17. Aben GR. Chest imaging tutorial. Michigan State University Web site. www.rad.msu.edu/Education/pages/Stu_Resources/Common/pages/Aben/IM_tutor/pages/intro.htm. Accessed October 14, 2006.
18. Gleeson CE, Spedding RL, Harding LA, Caplan M. The mediastinum – is it wide? *Emerg Med J.* 2001;18(3):183-185.
19. Bushong S. *Radiologic Science for Technologists.* 8th ed. St. Louis, MO: Elsevier Mosby; 2004:181,299.
20. Periodic Table of Elements Web site. www.dayah.com/periodic. Accessed October 12, 2006.
21. Siela D. Using chest radiography in the intensive care unit. *Crit Care Nur.* 2002;22(4):19-29.
22. Chandrasekhar AJ. Chest x-ray as a diagnostic tool. Loyola University Chicago Web site. www.meddean.luc.edu/lumen/MedEd/MEDICINE/PULMONAR/CXR/dxt1.htm. Accessed October 17, 2006.
23. Herring W. Tubes and lines: what, where and whoops. LearningRadiology.com Web site. www.learningradiology.com. Accessed October 19, 2006.

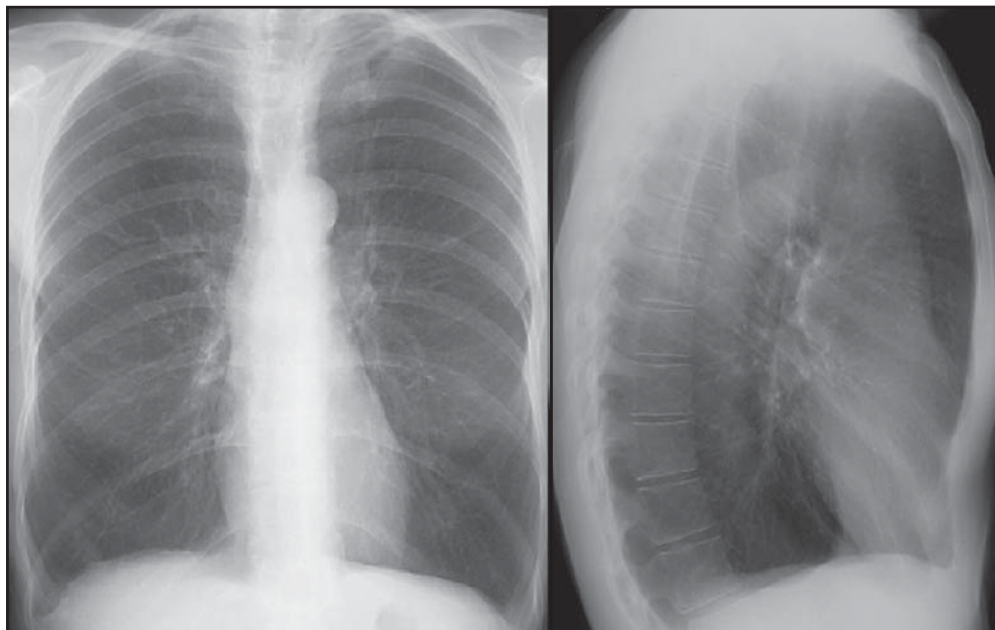


Figure 29. PA and lateral radiographs demonstrating emphysema. Note the barrel-shaped thoracic cavity and flattening of the diaphragms. (Image courtesy of S. Gay, University of Virginia Health Sciences Center Department of Radiology, Charlottesville.)

24. Dick E. Chest x-rays made easy. *studentBMJ*. 2000;8:303-346.
25. Alzouebi M. Paediatric chest radiographs. *studentBMJ*. 2005;13:309-352.
26. American Registry of Radiologic Technologists. Standards of Ethics, Code of Ethics number 6. www.arrt.org/ethics/standardethic.pdf. Accessed October 19, 2006.
27. Stewart RD, LaRosse A, Kaplan RM, Ilkhanipour K. Correct positioning of an endotracheal tube using a flexible lighted stylet. *Crit Care Med*. 1990;18(1):97-99.
28. Paran H, Butnaru G, Hass I, et al. Evaluation of a modified percutaneous tracheostomy technique without bronchoscopic guidance. *Chest*. 2004;126(3):868-871.
29. Miller P. Central access devices. *Radiol Technol*. 2006;77(4):297-305.
30. Scott WL. Central venous catheters. An overview of Food and Drug Administration activities. *Surg Oncol Clin N Am*. 1995;4(3):377-393.
31. Hocking G. Central venous access and monitoring. Nuffield Department of Anaesthetics, University of Oxford Web site. www.nda.ox.ac.uk/wfsa/html/u12/u1213_01.htm. Accessed October 21, 2006.
32. Bove-Geddes LA, Nichols HA. An overview of peripherally inserted central catheters. *Advanced Practice Nursing eJournal*. 2005;5(3). www.medscape.com/viewarticle/508939. Accessed October 22, 2006.
33. Heart and vascular center, cardiac devices, pacemakers. MetroHealth Web site. www.metrohealth.org/body
34. Heart disease: biventricular pacing to treat heart failure (cardiac resynchronization therapy). WebMD Web site. www.webmd.com/content/article/76/90188. Accessed October 23, 2006.
35. Mirowski M, Reid PR, Watkins L, Weisfeldt ML, Mower MM. Clinical treatment of life-threatening ventricular tachyarrhythmias with the automatic implantable defibrillator. *Am Heart J*. 1981;102(2):265-270.
36. Bardy GH, Johnson G, Poole JE, et al. A simplified, single-lead unipolar transvenous cardioversion-defibrillation system. *Circulation*. 1993;88(2):543-547.
37. Potter PA, Perry AG. *Fundamentals of Nursing Concepts, Process, and Practice*. 4th ed. St Louis, MO: Mosby-Year Book Inc; 1997:1405.
38. Kolbitsch C, Pomaroli I, Lorenz M, Gassner T, Luger J. Pneumothorax following nasogastric feeding tube insertion in a tracheostomized patient after bilateral lung transplantation. *Intensive Care Med*. 1997;23(4):440-442.
39. Blaiwas M, Lyon M, Duggal S. A prospective comparison of supine chest radiograph and bedside ultrasound for the diagnosis of traumatic pneumothorax. *Acad Emerg Med*. 2005;12(9):844-849.
40. Enlarged heart (cardiomegaly). MayoClinic.com Web site. www.mayoclinic.com/health/enlarged-heart/HQ00623. Accessed October 26, 2006.
41. Dimov V. Pneumoperitoneum due to sexual activity, clinical cases and images. The Cleveland Clinic Web site. <http://clinicalcases.blogspot.com/2004/03/pneumoperitoneum-due-to-sexual.html>. Accessed November 1, 2006.
42. The National Emphysema Foundation Web site. <http://emphysemafoundation.org>. Accessed November 13, 2006.
43. Gay S, Olazagasti J, Higginbotham J. Introduction to chest radiology. University of Virginia Health Sciences Center Department of Radiology Web site. www.med-ed.virginia.edu/courses/rad/cxr/index.html. Accessed November 13, 2006.

Dan L. Hobbs, M.S.R.S., R.T.(R)(CT)(MR), is an associate professor in the department of radiographic science at Idaho

State University in Pocatello. He has worked at Eastern Idaho Regional Medical Center for 18 years as an assistant radiology director and has taught for the past 7 years in the radiography program at Idaho State.

Reprint requests may be sent to the American Society of Radiologic Technologists, Communications Department, 15000 Central Ave. SE, Albuquerque, NM 87123-3909.

©2007 by the American Society of Radiologic Technologists.

Errata

The quiz for the Directed Reading article “Diagnosis and Treatment of Carotid Artery Disease” in the May/June issue included an error. Question #4 should have read: “Borderline cholesterol is considered _____ to _____ mg/ 100 mL.”

Also, in the “On the Job” column on patellar imaging published in the May/June issue, 2 radiographs were misidentified. The images are correctly reproduced and identified below.

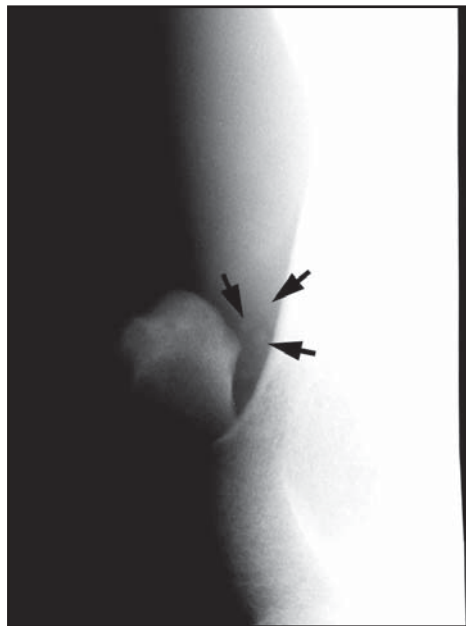

Figure 6. Posteromedial axial oblique projection of the left patella (anterolateral oblique position).

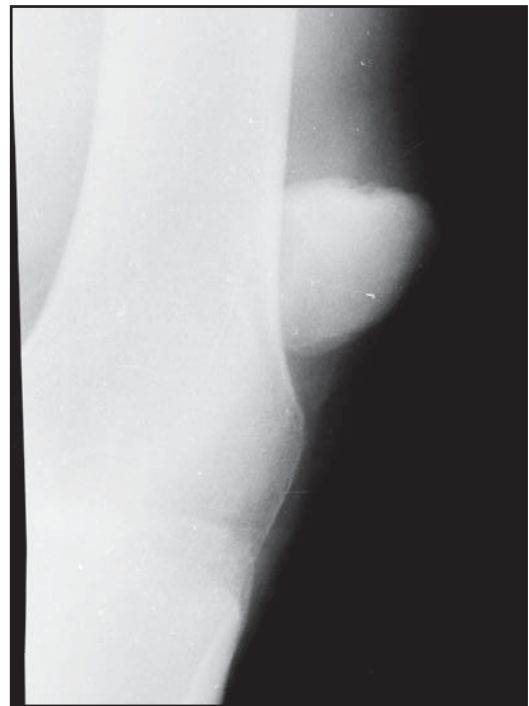

Figure 8. Posterolateral axial oblique projection of the left patella (anteromedial oblique position).