

## Carpal Box and Open Cup Radiography

**Dan L. Hobbs, M.S.R.S., R.T.(R)(CT)(MR)**, is an associate professor in the department of radiographic science at Idaho State University in Pocatello.

*Acknowledgement: Joshua Howard, a student in the radiographic science program at Idaho State University, contributed valuable research to this article.*

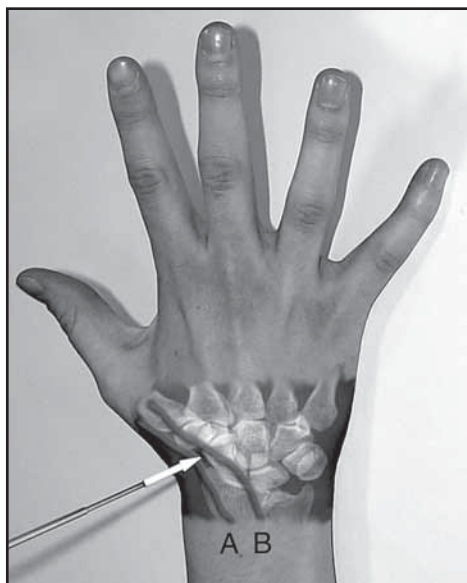Scaphoid fractures of the wrist are common and account for 71% of all carpal bone fractures. In the United States, approximately 345 000 new scaphoid fractures occur each year.<sup>1</sup> Additionally, statistics have shown that scaphoid fractures account for 2% to 7% of all orthopedic fractures; they are the most commonly undiagnosed fracture.<sup>2</sup> If an undiagnosed fracture is left without proper immobilization, a portion of the scaphoid may die; therefore, it is imperative that proper diagnosis, radiographic evaluation and therapeutic treatment begin as soon as possible.

The purpose of this article is to acquaint the radiographer with a few non-traditional methods used to image this fracture. This will be accomplished by first reviewing scaphoid anatomy, which

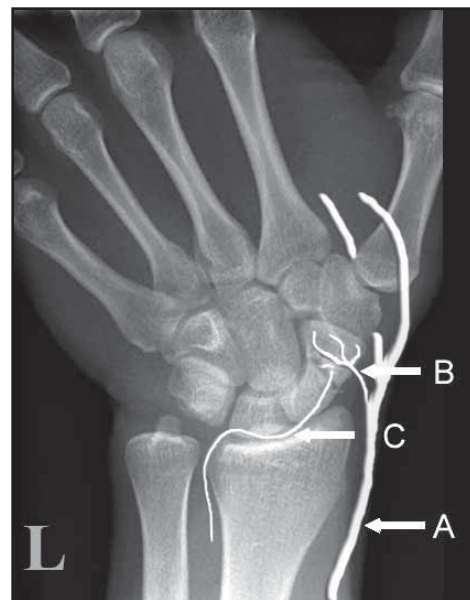
will include a discussion of the blood supply to this bone. Next, there will be a brief discussion of the mechanism of injury, and the article will conclude with a review of 3 positioning techniques that can be employed to help diagnose scaphoid fractures.

### Anatomy

The scaphoid is located on the radial side of the wrist in the anatomical snuff box, which is located between the extensor pollicis brevis and extensor pollicis longus tendons. (See Fig. 1.) It is the largest bone in the proximal row of carpals and can be described as being complex because of its twisted shape; some describe it as being boat-shaped.<sup>3</sup> It articulates with the radius, lunate, capitate, trapezoid and trapezium. It is about the size of a peanut shell and is covered in articular cartilage. Because of the bone's small size, the blood supply to the scaphoid is very fragile.



**Fig. 1.** Anatomical snuffbox. A hollow depression that is seen on the radial aspect of the wrist when the thumb is extended fully. It is called the anatomical snuffbox because snuff (powdered tobacco) could be placed there and then inhaled by the user. This is the location of the scaphoid. An arrow points to the snuff box. A. Extensor pollicis brevis tendon. B. Pollicis longus tendon. These 2 tendons aid in abduction and extension of the thumb and extend to the distal phalange.



**Fig. 2.** Arterial blood supply to the scaphoid bone. The wrist is positioned in ulnar deviation. A. Radial artery. B. Volar scaphoid branch. C. Anterior interosseous artery. If the volar scaphoid branch is torn during trauma, the scaphoid is at risk for losing its blood supply.

A fracture almost always interrupts the nutrient supply to this bone. Quite often a portion of the bone loses its blood supply completely. This condition leads to a process called avascular necrosis. If left untreated, it can cause severe traumatic arthritis of the joint. This type of arthritis is different from rheumatoid or osteoarthritis because it only occurs in the injured joint and does not spread to other joints in the body.

The blood vessels that feed the scaphoid are more plentiful in the distal portion of the bone. It is there that the scaphoid is fed by the radial artery after it has subdivided into the volar scaphoid branches. The intraosseous and extraosseous vessels provide a vascular supply to the rest of the scaphoid bone. (See Fig. 2.) The inferior pole has poor vascular circulation, which increases the chances of necrosis after traumatic injury in this area.

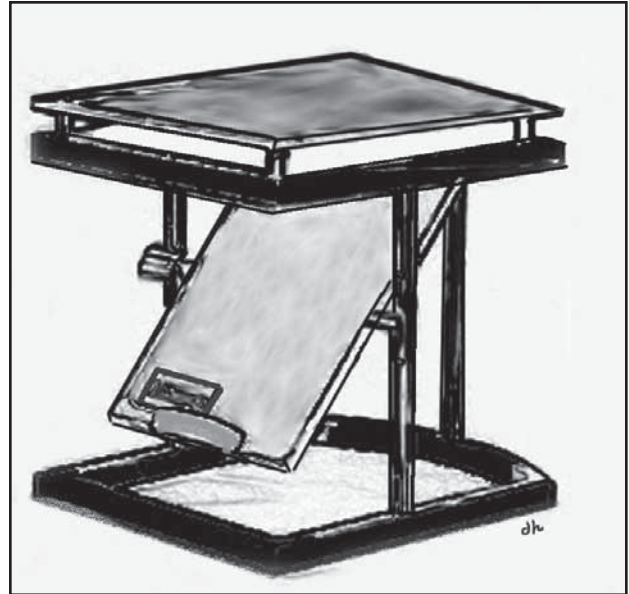### Mechanism of Injury

The mechanism of injury is generally from impact on an outstretched hand due to a fall. Usually the palmar surface of the hand near the scaphoid receives the blunt force causing the scaphoid to fracture. Along with pain and tenderness in the anatomical snuffbox, the patient has swelling on the radial side of the wrist. After a complete examination of the affected area, the practitioner will decide whether to order radiographs, magnetic resonance (MR) imaging, computed tomography (CT) or a bone scan.

### Imaging

MR and CT can assist in the diagnosis of scaphoid injuries. In a recent study, the sensitivity of MR has been evaluated with regard to its usefulness in assessing scaphoid fractures. Brydie et al<sup>4</sup> have shown that MR is the definite gold standard to evaluate of these fractures; nevertheless, MR is more expensive and is not an immediate option in all instances. Likewise, bone scans have been recommended for this malady. Their cost is lower than MR or CT, but they are not immediately available. Consequently, diagnostic radiography is the first imaging choice in many cases.

The initial examination consists of a radiographic scaphoid series. The routine projection includes a posteroanterior (PA) of the wrist; additionally, lateral, oblique and ulnar deviation positions are performed. These radiographs are typical and will not be discussed further. However, there are a few atypical methods that may be of interest to the reader. They include carpal box and open cup radiography.



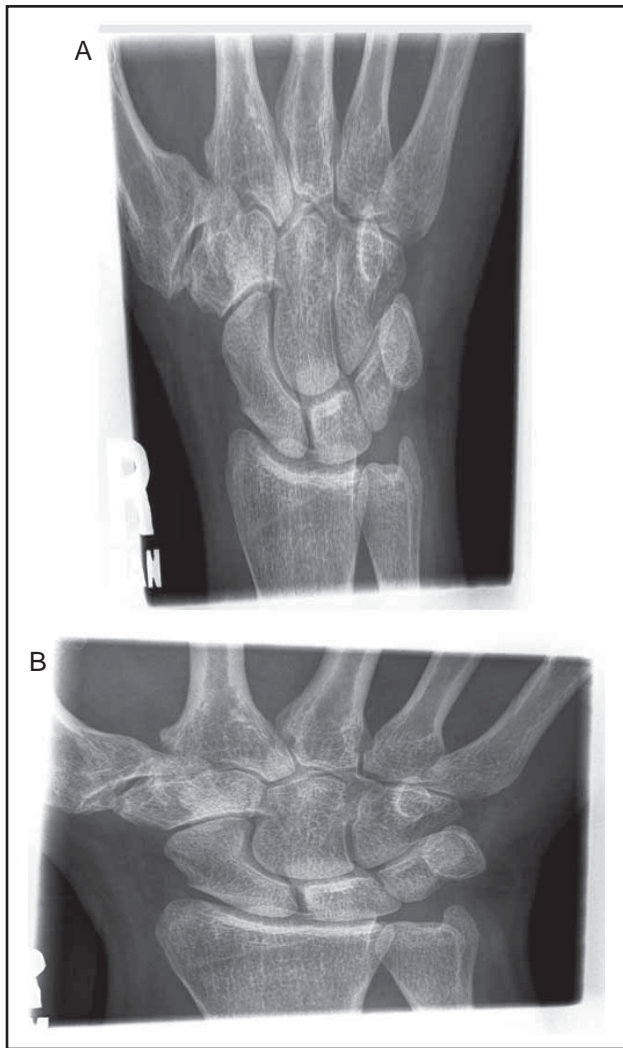
**Fig. 3.** *Carpal Box apparatus. This box allows the radiographer to take an elongated or widened image of the wrist.*

### Methods

#### *Carpal Box Radiography (Method I)*

Carpal box radiography was described in 1996 by Roolker et al<sup>5</sup> and requires an apparatus called a carpal box to perform the radiographs. (See Fig. 3) This box was developed to provide a magnified and distorted image of the carpal bones. This is accomplished by the oblique placement of the imaging receptor (IR) in the carpal box. This device also increases the object to IR distance (OID) of the wrist. The obliquity of the IR results in an elongation or widening of the image. Elongation occurs when the wrist is placed in the longitudinal orientation in relation to the IR. Widening occurs when the wrist is placed in the transverse orientation in relation to the IR. Both positions magnify the carpals and produce images that are distorted. Part placement is performed at the discretion of the practitioner.

With the carpal box method less bone-to-bone overlap is visible on the radiograph compared to routine images of the wrist. Consequently, the resultant magnified, elongated or widened image can be used to better evaluate an otherwise occult fracture. (See Fig. 4.) It is important that the radiographer use a small focal spot when making the exposure. Additionally, extremity cassettes and film are recommended.



**Fig. 4.** Carpal box images. These images were obtained with a distance of 44 inches source-to-imaging receptor (IR) distance (SID) and an IR obliquity of 55°. The wrist can be placed longitudinally (A) or transversely (B) in relation to the IR.

#### *Carpal Box Radiography (Method II)*

Regrettably, the carpal box apparatus is not available in most imaging departments. An improvised method can be adapted by using a sponge and stool in place of the carpal box apparatus. This is accomplished by placing the wrist on the x-ray table top. The table top then is advanced over the stool, while the obliquity of the IR is maintained by resting it on a sponge underneath the table. (See Fig. 5.) This provides an innovative way of getting the same results without the aid of the carpal box.

#### *Open Cup Method (Method III)*

The open cup method has not been investigated in the literature but has been performed successfully at several imaging centers in the Northwest. Essentially, it is a magnification view and is performed by cutting out the bottom from a 16 oz barium cup. The cup then is inverted and placed on the IR. Next, the radiographer positions the anatomic snuff box within the hole of the cup. The exposure is made with the wrist in ulnar deviation and the resultant radiograph demonstrates the magnified scaphoid. (See Fig. 6.) Though non-traditional, this method may prove valuable because the rim of the cup produces a ring-like window on the radiograph. This window might be distracting to some; however, the magnified scaphoid in the circular window makes it easy for the practitioner to evaluate subtle injuries to this bone.

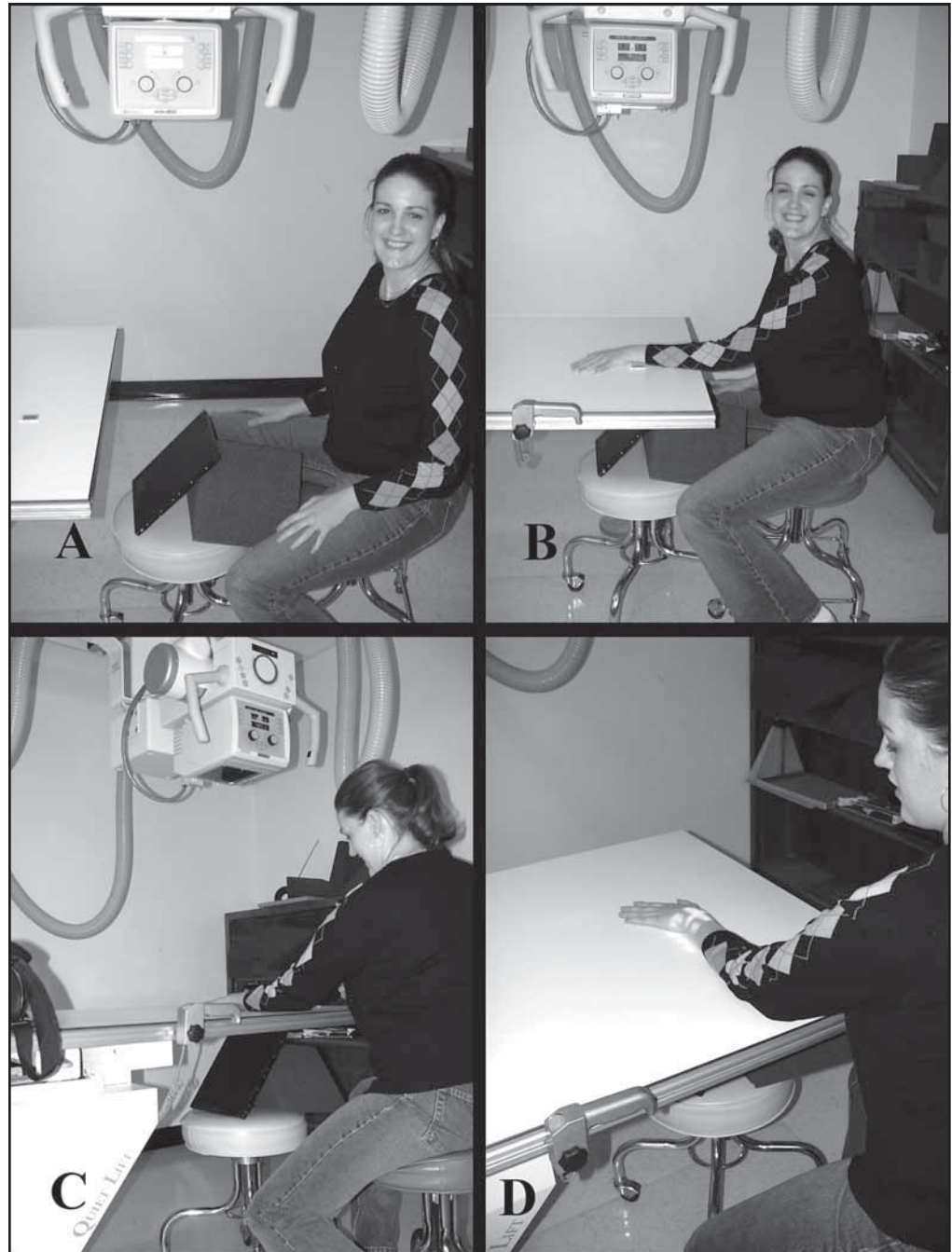
#### **Discussion**

Conventional radiography of the wrist does not always confirm a scaphoid fracture diagnosis. In such cases, magnification, elongation and widening by using the carpal box or open cup methods may aid in detection. When performing these methods, it is imperative to use a small focal spot and extremity cassettes; these techniques increase anatomic detail and compensate for the increased OID. The advantage of carpal box radiography is that the resultant images can demonstrate otherwise occult fractures. The disadvantage is that the box is not readily available; however, an improvised way to perform this procedure is relatively simple.

It is also interesting to note that Toth et al<sup>6</sup> evaluated carpal box radiography for detecting scaphoid fractures in 2003. They found that 90% (n=146) of the fractures in their study were diagnosed by carpal box radiography and only 6.8% needed referral for CT or MR imaging. They determined that the sensitivity of carpal box radiography at initial presentation was 81.6%. This means that carpal box radiography can be used as a primary tool in the early diagnostic phase in place of more expensive CT or MR scans.

The open cup method has not been substantiated in the literature, but is an interesting concept that may warrant further investigation. An advantage of this method is that barium cups are readily available in most imaging departments. Granted, a sponge could be used for this position; however, the rim of the cup aids as a window on the radiograph, somewhat accentuating the scaphoid bone. The disadvantage is that elongation of the scaphoid is difficult to obtain because angling the



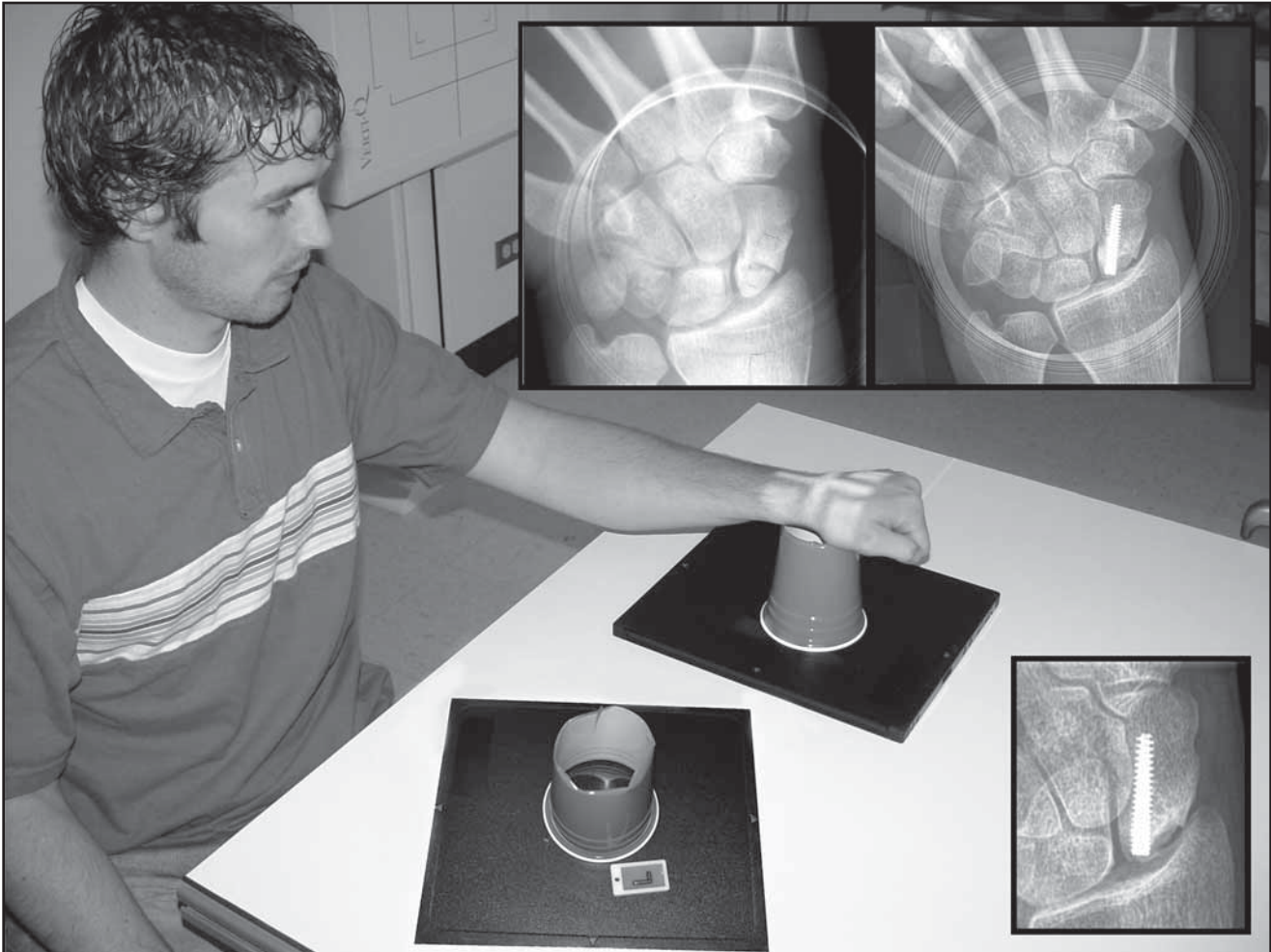

**Fig. 5.** *Improvised method.*  
**A.** *The IR is placed at approximately 55° obliquity on a stool in front of the patient; the tube is centered to the cassette.*  
**B.** *The table top is advanced over the IR and the patient's arm is extended longitudinally in relation to the cassette.*  
**C.** *This is the same setup, but now the patient is oriented with the wrist positioned transversely in relation to the IR.*  
**D.** *Hand in ulnar deviation and the x-ray beam collimated to the wrist.*

tube projects the image out of the circular rim of the cup. Although the use of a sponge may be better, the open cup method is a unique idea.

In conclusion, most examinations begin in the imaging department with plain radiographs. If a fracture

is demonstrated, treatment can begin; however, if no fracture is evident, but highly suspected, additional investigation might include the carpal box or the open cup methods before using MR, CT or nuclear medicine. To avoid one of these more expensive options, the



**Fig. 6.** Open cup method. Magnified radiographs at top of the photo demonstrate before and after screw insertion of a nonunion scaphoid fracture. Radiograph below demonstrates PA projection in ulnar deviation that has been collimated to eliminate the circular ring formed by the shadow of the cup.

radiographer may suggest one of these methods the next time a patient presents with pain in the anatomic snuff box. ♦

### References

1. Boles C. Wrist, scaphoid fractures and complications. eMedicine. Available at: [www.emedicine.com/radio/topic747.htm#section~x-ray](http://www.emedicine.com/radio/topic747.htm#section~x-ray). Accessed December 30, 2005.
2. Nishihara R. The dilemmas of a scaphoid fracture: a difficult diagnosis for primary care physicians. *Hospital Physician*. [electronic version] 2000;24-40. Available at: [www.turner-white.com/pdf/hp\\_mar00\\_scaphoid.pdf](http://www.turner-white.com/pdf/hp_mar00_scaphoid.pdf). Accessed December 30, 2005.
3. Bontrager KW, Lampignano JP. *Textbook of Radiographic Positioning and Related Anatomy*. 6th ed. St Louis, Mo: Mosby-Year Book Inc; 2005:132.
4. Brydie A, Raby N. Early MR in the management of clinical scaphoid fracture. *Br J Radiol*. 2003;76:296-300.
5. Roolker W, Tiel-van Buul MM, Bossuyt PM, Bakker AJ, et al. Carpal Box radiography in suspected scaphoid fracture. *J Bone Joint Surg Br*. 1996;78(4):535-539.
6. Toth F, Mester S, Cseh G, Bener A, et al. Modified Carpal Box technique in the diagnosis of suspected scaphoid fractures. *Acta Radiol*. 2003;44(3):319-325.