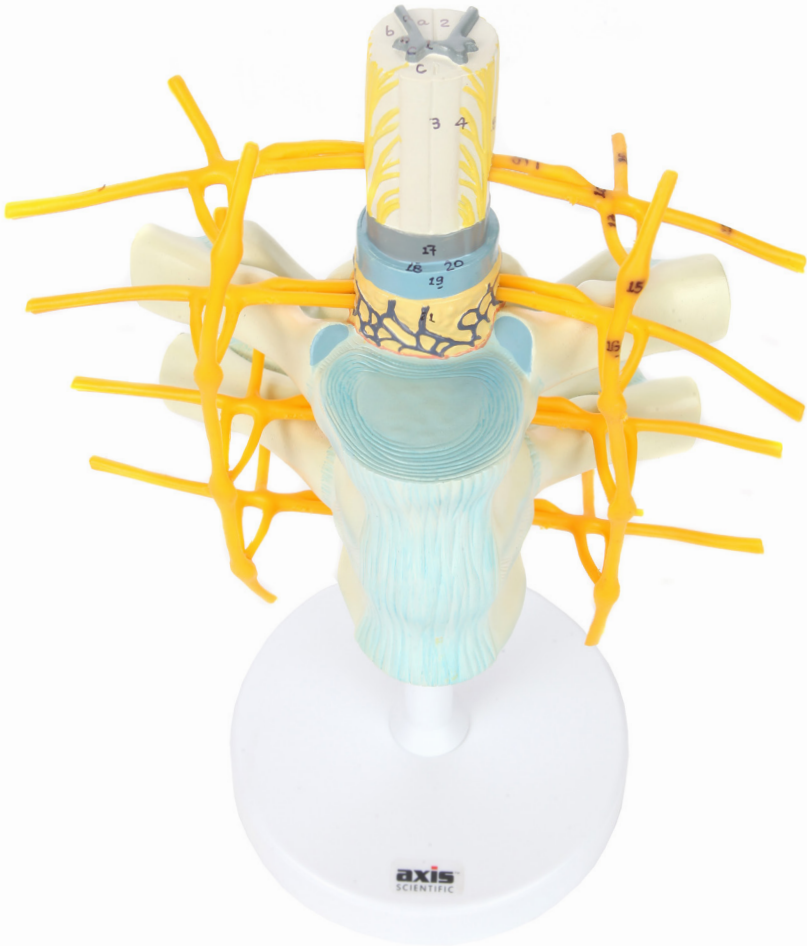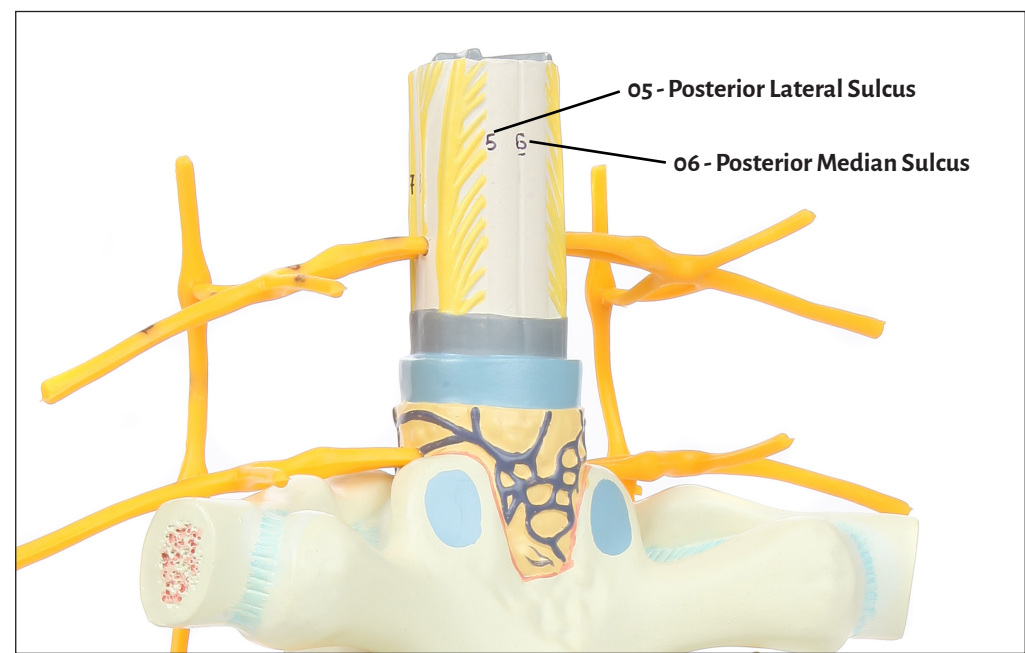
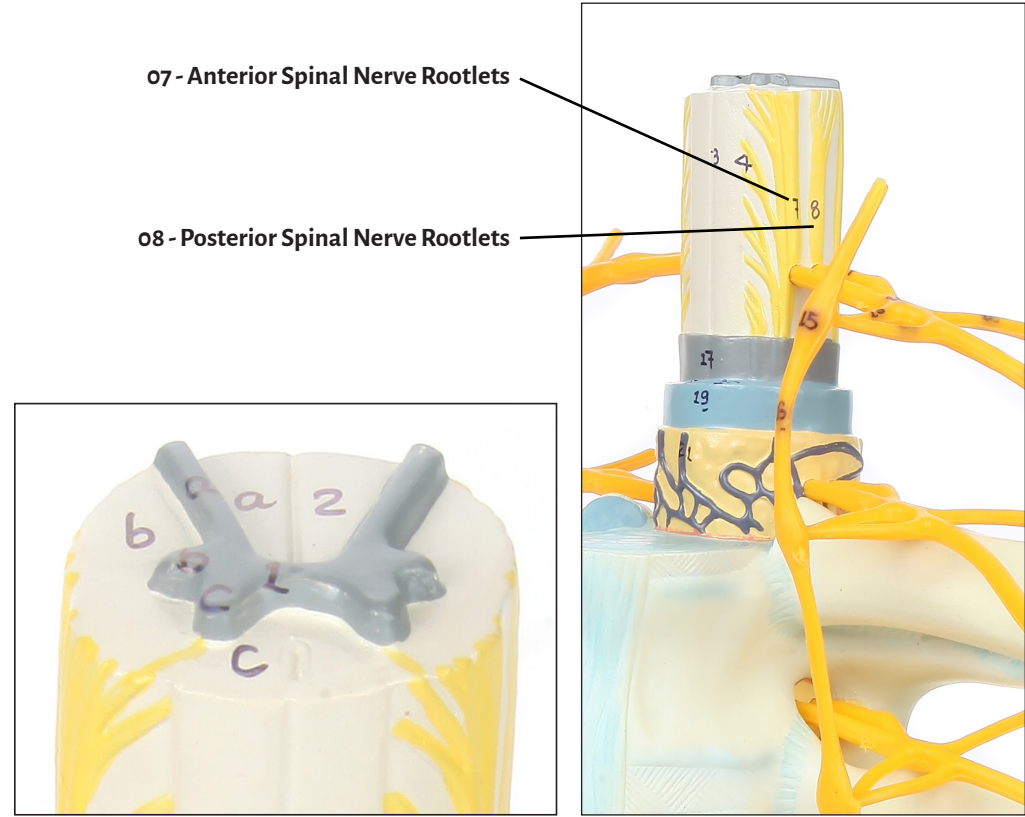
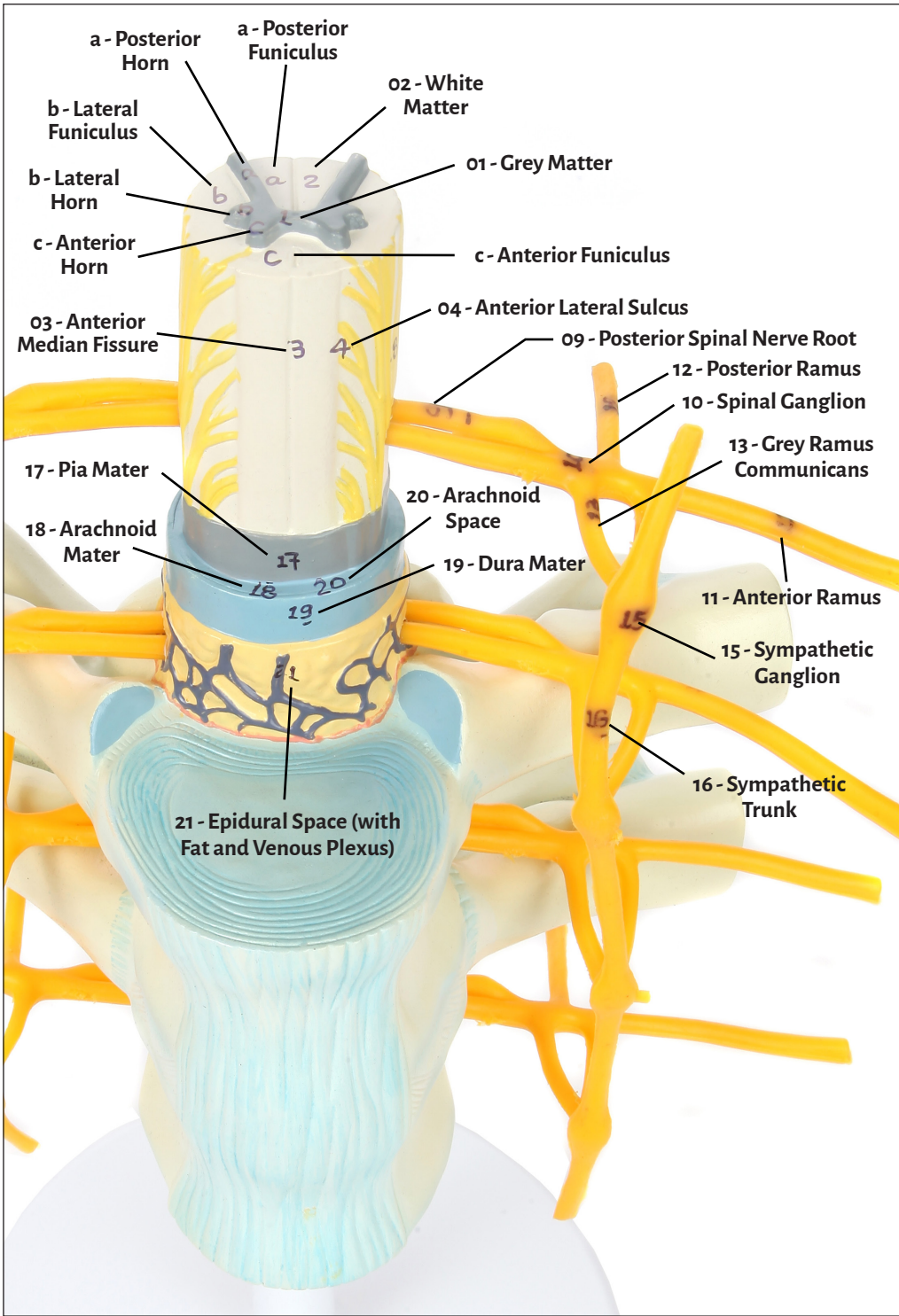




Axis Scientific Thoracic Vertebrae & Spinal Cord

A-105863





- 01 - Grey Matter
 - 02 - White Matter
 - 03 - Anterior Median Fissure
 - 04 - Anterior Lateral Sulcus
 - 05 - Posterior Lateral Sulcus
 - 06 - Posterior Median Sulcus
 - 07 - Anterior Spinal Nerve Rootlets
 - 08 - Posterior Spinal Nerve Rootlets
 - 09 - Posterior Spinal Nerve Root
 - 10 - Spinal Ganglion
 - 11 - Anterior Ramus
 - 12 - Posterior Ramus
 - 13 - Grey Ramus Communicans
 - 14 - White Ramus Communicans
 - 15 - Sympathetic Ganglion
 - 16 - Sympathetic Trunk
 - 17 - Pia Mater
 - 18 - Arachnoid Mater
 - 19 - Dura Mater
 - 20 - Arachnoid Space
 - 21 - Epidural Space (with Fat and Venous Plexus)
- Spinal Cord White Matter
- a - Posterior Funiculus
 - b - Lateral Funiculus
 - c - Anterior Funiculus
- Spinal Cord Grey Matter
- a - Posterior Horn
 - b - Lateral Horn
 - c - Anterior Horn

